

**HEMANGIOBLASTOMAS OF THE CENTRAL NERVOUS SYSTEM AND RETINA  
IMPACT OF VON HIPPEL-LINDAU DISEASE**

**Mika Niemelä  
Helsinki 2000**

**Hemangioblastomas of the Central Nervous System and Retina  
Impact of von Hippel-Lindau Disease**

**Mika Niemelä**

Departments of Neurosurgery and Ophthalmology  
Helsinki University Central Hospital  
Helsinki, Finland

Academic Dissertation

Helsinki 2000

To be publicly discussed with the permission of  
the Medical Faculty of the University of Helsinki  
in Lecture Hall 1 of Töölö Hospital  
on April 28th, 2000, at 12 noon

ISBN 951-45-9168-2 (PDF version)  
Helsingin yliopiston verkkojulkaisut  
Helsinki 2000

## **SUPERVISORS**

### **Docent Juha Jääskeläinen**

Neurosurgery

Helsinki University Central Hospital

Helsinki, Finland

### **Docent Paula Summanen**

Ophthalmology

Helsinki University Central Hospital

Helsinki, Finland

## **REVIEWERS**

### **Docent Pauli Helén**

Neurosurgery

Tampere University Hospital

Tampere, Finland

### **Docent Heikki Minn**

Oncology

Turku University Hospital

Turku, Finland

## **OPPONENT**

### **Professor Peter McL Black**

Neurosurgery

Harvard Medical School

Boston, USA

# CONTENTS

<b>LIST OF ORIGINAL PUBLICATIONS</b>	6
<b>ABBREVIATIONS</b>	7
<b>INTRODUCTION</b>	8
<b>REVIEW OF THE LITERATURE</b>	10
<b>1. Hemangioblastomas (HB)</b>	10
<i>Hemangioblastomas of the CNS</i>	10
<i>Hemangioblastomas of the retina</i>	10
<b>2. von Hippel-Lindau disease (VHL)</b>	11
<i>Definition</i>	11
<i>Historical aspects</i>	12
<i>Genetics of VHL</i>	12
<i>Manifestations of VHL</i>	13
<i>Prognosis of VHL</i>	15
<b>3. Problems of treatment in VHL</b>	15
<i>Hemangioblastomas of the CNS</i>	15
<i>Hemangioblastomas of the retina</i>	16
<i>Renal cell carcinoma (RCC)</i>	17
<b>4. Novel treatment methods</b>	18
<i>Stereotactic radiotherapy</i>	18
<i>Antiangiogenic therapy</i>	19
<b>AIMS OF THE STUDY</b>	21
<b>PATIENTS, TUMORS, AND METHODS</b>	22

<b>1. Patient Series I-IV</b>	22
<b>2. Histological and proliferation analysis (I)</b>	25
<b>3. Finnish Cancer Registry (I-II)</b>	25
<b>4. Pedigree analysis (I-II)</b>	26
<b>5. Mutation analysis (I-II)</b>	26
<b>6. VHL criteria (I-IV)</b>	27
<b>7. Statistical methods (I-III)</b>	27
<b>RESULTS AND DISCUSSION</b>	28
<b>1. VHL prevalence and long-term prognosis of 110 patients with HBs of the CNS (I)</b>	28
<i>The prevalence of VHL in patients with HB(s) of the CNS</i>	28
<i>Charateristics of VHL patients</i>	29
<i>HB of the CNS</i>	29
<i>HB of the retina</i>	30
<i>Lesions suggestive of VHL</i>	31
<i>Long-term survival of patients with HB(s) of the CNS</i>	32
<i>Early detection of VHL lesions</i>	32
<b>2. VHL prevalence and long-term prognosis of vision in 36 patients with HBs of the retina (II)</b>	33
<i>Distinction of VHL patients among patients with retinal HB(s)</i>	33
<i>Definite VHL patients</i>	34
<i>Suspect VHL patients</i>	34
<i>Non-VHL patients</i>	35
<i>VHL prevalence in retinal HBs</i>	36
<i>Long-term prognosis of vision in patients with retinal HB(s)</i>	36
<i>Early detection of VHL lesions</i>	37
<b>3. Gamma knife radiosurgery in 11 HBs of the CNS (III)</b>	38
<i>Response of the solid part</i>	38
<i>Response of the adjacent cyst</i>	39
<i>Morbidity and tumor margin dose</i>	39

<b>4. IFN<math>\alpha</math>2a treatment in 18 HBs of the CNS and retina (IV)</b>	40
<i>Patients and HBs</i>	40
<i>Overall response</i>	40
<i>Dosage of IFN</i>	41
<i>Future trends</i>	42
<b>CONCLUSIONS</b>	43
<b>SUMMARY</b>	44
<b>FIGURES OF VHL LESIONS</b>	46
<b>1. HBs of the CNS</b>	46
<b>2. RCC and cysts</b>	47
<b>3. HBs of the retina</b>	48
<b>ACKNOWLEDGMENTS</b>	50
<b>REFERENCES</b>	52
<b>ORIGINAL ARTICLES</b>	67

## **LIST OF ORIGINAL PUBLICATIONS**

This thesis is based on the following publications, referred to in the text by their Roman numerals:

**I Niemelä M, Lemeta S, Summanen P, Böhling T, Sainio M, Kere J, Poussa K, Sankila R, Haapasalo H, Kääriäinen H, Pukkala E, Jääskeläinen J.**

Long-term prognosis of haemangioblastoma of the CNS: impact of von Hippel-Lindau disease. *Acta Neurochir* 141:1147-1156, 1999

**II Niemelä M, Lemeta S, Sainio M, Rauma S, Pukkala E, Kere J, Böhling T, Laatikainen L, Jääskeläinen J, Summanen P.**

Hemangioblastoma of the retina: impact of von Hippel-Lindau disease. *Invest Ophthalmol Vis Sci*. Accepted for publication.

**III Niemelä M, Lim YJ, Söderman M, Jääskeläinen J, Lindquist C.**

Gamma knife radiosurgery in 11 hemangioblastomas. *J Neurosurg* 85:591-596, 1996

**IV Niemelä M, Mäenpää H, Salven P, Summanen P, Poussa K, Laatikainen L, Jääskeläinen J, Joensuu H.**

Treatment of 18 hemangioblastomas in 4 patients with interferon alpha-2a. Submitted.

## ABBREVIATIONS

AVM	arteriovenous malformation
CNS	central nervous system
CT	computed tomography
DNA	deoxyribonucleic acid
ELST	endolymphatic sac tumor
EPO	erythropoietin
FA	fluorescein angiography
FCR	Finnish Cancer Registry
FISH	fluorescence in situ hybridization
GK	gamma knife
Gy	Gray
HB	hemangioblastoma
HPC	hemangiopericytoma
HUCH	Helsinki University Central Hospital
IFN $\alpha$ 2a	interferon alpha-2a
IU	International Unit
MIB-1	MIB-1 monoclonal antibody
MRI	magnetic resonance imaging
NF2	neurofibromatosis 2
PCR	polymerase chain reaction
PRC	Population Registry Center
pVHL	von Hippel-Lindau gene product
RCC	renal cell carcinoma
RS	radiosurgery
SIADH	syndrome of inappropriate secretion of antidiuretic hormone
SR	stereotactic radiotherapy
US	ultrasonography
VEGF	vascular endothelial growth factor
VHL	von Hippel-Lindau disease
WHO	World Health Organization

## INTRODUCTION

Von Hippel-Lindau disease (VHL) is a rare dominantly inherited cancer syndrome predisposing to multiple hemangioblastomas (HB) of the CNS and retina, renal cell carcinomas (RCC), pancreatic carcinoma, pheochromocytomas, and visceral cysts. VHL is caused by a defect in the VHL tumor suppressor gene in chromosome 3p25-p26. VHL clearly reduces the length of life, as the mean age at death is 40 to 50 years. Due to advances in microsurgery, RCC has exceeded HBs of the CNS as the leading cause of death in VHL.

The HB is a highly vascular, benign and well-circumscribed, slowly growing solid or cystic neoplasm of the CNS and retina. (1) *HB of the CNS* is regarded to be sporadic in 60-90% of the cases and then it is typically a single, cystic lesion of the cerebellum, presenting at the average age of somewhat over 40 years. In VHL, HBs of the CNS appear 10 years earlier. Microsurgery is the treatment of choice aided, if necessary, by preoperative embolization to reduce intraoperative bleeding. Radiosurgery offers a non-invasive means to treat HBs in eloquent brain areas. (2) *HB of the retina* originates from the inner, mid-peripheral retina, and is histologically identical to HB of the CNS. Retinal HB is the first manifestation in about half of the VHL patients at the mean age of 25 years, and is usually bilateral and multifocal, or becomes so over the years. There are sporadic retinal HBs without VHL, but their prevalence has remained undefined. Retinal HBs, even when small and asymptomatic, should be treated with laser or cryocoagulation to prevent loss of vision.

There is increased morbidity related to repeated microsurgery and radiosurgery of HBs of the CNS, as well as coagulation of retinal HBs. Therefore, it is justifiable to seek other approaches to treat multiple HBs. Antiangiogenic tumor therapy is targeted to small foci of migrating and proliferating endothelial cells in capillaries at sites of angiogenesis, in an attempt to inhibit tumor growth. Interferon-alpha (IFN $\alpha$ ) is a well-tolerated drug with immunomodulatory, antiproliferative and antiangiogenic activities. It has an established role in certain types of cancer, and it is especially effective in life-threatening hemangiomas of the liver and facial areas in children.

Long-term follow-up data on patients with HBs of the CNS and/or retina, treated with population responsibility and distinction of VHL, have remained scarce. The effect of radiosurgery in HBs of the CNS remains undetermined. There are no published data on the

effect of IFN $\alpha$  therapy in HBs of the CNS and retina. The aims of this thesis were to study the VHL prevalence and long-term prognosis of patients with HBs of the CNS and retina, the results of gamma knife radiosurgery in HBs of the CNS, and the impact of 12-month IFN $\alpha$ 2a therapy in HBs of the CNS and retina.

## REVIEW OF THE LITERATURE

### 1. Hemangioblastomas (HB)

#### *Hemangioblastomas of the CNS*

The HB is a highly vascular, benign and well-circumscribed, slowly growing solid or cystic neoplasm of the CNS and retina composed of stromal cells, endothelial cells, pericytes, and mast cells<sup>14,17</sup>. The origin of the stromal cells, believed to be the true neoplastic cells of HB tissue, is still undefined<sup>17</sup>. HB may cause polycythemia by secreting erythropoietin from stromal or mast cells<sup>16,73,113,119</sup>. HB of the CNS is one of the manifestations of von Hippel-Lindau disease (VHL) (see below), but is regarded to be sporadic in 60-90% of the cases, and then it is typically a single, cystic lesion of the cerebellum<sup>96</sup>, brain stem or upper cervical medulla, presenting at the average age of somewhat over 40 years<sup>12,108,117,139</sup>. Supratentorial HBs are rare<sup>138,150</sup>. HBs have also been described to occur rarely in spinal nerve roots<sup>60,167</sup>, peripheral nerves<sup>13,24</sup>, and the optic nerve<sup>8,83,145</sup>. Microsurgery is the treatment of choice in HBs of the CNS<sup>36,138,163</sup> aided, if necessary, by preoperative embolization to reduce intraoperative bleeding<sup>49,156,164</sup>.

#### *Hemangioblastomas of the retina*

The retina consists of 10 layers and contains blood vessels in its inner layers<sup>38,43</sup>. After photoreception by the rods and cones, the bipolar cells in the inner nuclear layer transmit their signals to the ganglion cells, the axons of which form the optic nerve. The central area of the retina (macula lutea) has the highest visual acuity in its cone-rich center, i.e. the fovea (diameter 150  $\mu\text{m}$ ). HB of the retina originates from the inner, mid-peripheral retina, and is histologically identical to HB of the CNS<sup>68</sup>. Mature HBs resembling 'sugar-powdered' raspberries and the adjoining dilated, tortuous arterioles and venules (feeder vessels) are distinctive enough to permit visual diagnosis after pupillary dilatation with indirect ophthalmoscopy, Goldmann 3-mirror contact lens or non-contact lens fundus examination<sup>123,174</sup>. Incipient HBs are small, reddish or grayish dots, without abnormal

adjoining vessels<sup>151</sup>. In retinal HBs, fluorescein angiography (FA) shows an arteriovenous shunt with leakage of dye due to incompetent capillary walls. FA may help to detect small HBs not yet accompanied by enlarged vessels<sup>155</sup>, but incipient lesions may fail to fill with fluorescein. For this reason, and its possible side-effects, FA is not recommended as a screening tool<sup>123,151</sup>. In differential diagnosis, HBs of the optic disc<sup>10,76</sup> may resemble papillitis, papilledema, chorioiditis, or chorioidal hemangioma<sup>76,155,177</sup>. Cavemous hemangiomas of the retina appear as grape-like clusters of dilated vascular sacs without pronounced alteration in the adjacent arterioles and venules<sup>7</sup>. Coats' disease with dilated, tortuous and leaking retinal venules may cause exudative detachment of the retina in children and teenagers<sup>155</sup>.

HBs of the retina can be asymptomatic for years, and may even regress spontaneously<sup>172</sup>. Usually, however, symptoms such as flashing and floaters occur and there is progressive visual impairment due to leakage from the incompetent capillary walls of HBs. This leads to secondary changes in the vitreous and retina such as premature posterior vitreous detachment, retinal break, vitreous hemorrhage, lipid exudates and edema in the macula, or preretinal fibrosis<sup>123,174</sup>. In advanced cases, total retinal detachment may occur either due to accumulation of fluid between the photoreceptor layer and the retinal pigment epithelium caused by excessive leakage from large HBs, vitreous traction caused by vitreous strands and epiretinal membranes and/or retinal breaks<sup>123</sup>. Early lesions are easy to eradicate, and they carry the lowest risk of complications. Therefore, retinal HBs should be treated even when small and asymptomatic with laser or cryocoagulation for a better prognosis of vision<sup>174</sup>.

## **2. von Hippel-Lindau disease (VHL)**

### *Definition*

VHL is a rare (1/36 000 alive births) dominantly inherited cancer syndrome caused by a tumor suppressor gene defect predisposing to multiple hemangioblastomas (HB) of the CNS and retina, renal cell carcinomas (RCC), pheochromocytomas, pancreatic carcinoma, and cysts in the kidneys, liver, and pancreas<sup>31,52,53,67,97,104,118,138,176</sup>. Also, several other less common lesions have been described<sup>118,138</sup>, such as epididymal

cystadenomas<sup>2</sup>, and endolymphatic sac tumors<sup>82,109</sup>. Diagnosis of VHL is based on VHL gene mutation analysis<sup>94,161</sup> and/or clinical manifestations over long-term follow-up<sup>31,108,111,114</sup>. A patient with HB of the CNS or retina is classified as having VHL if the patient has a germline mutation, family history of VHL, or other VHL-related neoplasms (HBs of the CNS or retina, RCC, pheochromocytoma).

### *Historical aspects*

In 1911, Eugen von Hippel, a German ophthalmologist, defined retinal HBs as a cystic capillary angiomas of congenital origin<sup>176</sup>. In 1926-1927, Arvid Lindau, a Swedish pathologist, disclosed the relationship between HBs of the CNS and retina and visceral lesions<sup>97,98</sup>. In 1992, Grossniklaus et al.<sup>68</sup> showed that HBs of the retina are histologically identical to their counterparts in the CNS. In 1993, Latif et al.<sup>93</sup> identified the VHL tumor suppressor gene, which, together with modern imaging of the CNS and abdomen, have improved the diagnosis of VHL also in asymptomatic carriers.

### *Genetics of VHL*

VHL is caused by a defect in the VHL tumor suppressor gene in chromosome 3p25-p26<sup>94,141</sup>. The function of the VHL gene is not fully understood<sup>41,144</sup>, but loss of the gene product (pVHL) function<sup>44,45,75,84,126</sup> in normoxic conditions may lead to an inappropriate expression of hypoxia-inducible proteins such as the vascular endothelial growth factor (VEGF)<sup>55,80,133</sup>, which may account for the hypervascular nature of VHL-associated neoplasms<sup>64,70,162</sup>. VHL is an autosomal dominant trait with a high penetrance, as almost 100 % of the carriers of a VHL gene defect will develop clinical manifestations by the age of 60 years<sup>108</sup>. Their children have a 50% risk of getting the disease<sup>104,108,118</sup>. Half of the VHL cases are familial and half are caused by new mutations, estimated to occur at  $4.4 \times 10^6$  gametes per generation<sup>104</sup>. Several mutations have been described, and a VHL gene mutation database has been established<sup>11</sup>. Mutations are heterogeneous in type and position, and VHL shows intra- and interfamilial differences in phenotype<sup>37,81,138,142,171,178</sup>. Direct sequencing of the VHL gene has an expected detection rate of 60-70% of the VHL gene mutations but it misses

deletions<sup>161,178</sup>. Quantitative Southern blotting can be used to detect deletions of the entire VHL gene, Southern blotting to detect partial deletions, and fluorescence in situ hybridization (FISH) to confirm deletions of the entire VHL gene<sup>161</sup>. By combining these techniques, virtually all mutations can be detected in definite VHL families<sup>161</sup>.

There is some genotype-phenotype correlation: germline mutations predicted to inactivate the VHL protein are associated with RCC and HBs of the CNS without pheochromocytoma (Type 1), and germline mutations predicted to produce full-length VHL proteins are associated with pheochromocytoma and other VHL manifestations (Type 2)<sup>25,37,106,161,178</sup>. However, it is still not possible to predict reliably the severity and spectrum of VHL manifestations based on any single VHL gene defect.

### *Manifestations of VHL*

Multiple HBs of the CNS are a typical manifestation of VHL. HBs of the CNS occur about 10 years earlier than their sporadic counterparts, at the average age of about 30 years<sup>12,108,117,139</sup>. Of the patients with HBs of the CNS, 10-40% have VHL<sup>12,107,117,139</sup>. In VHL, as compared to sporadic cases, HBs of the CNS are more often located in the brainstem and spinal cord<sup>138</sup>. Analogous to cerebellar HBs that often produce cysts, spinal cord HBs may induce syringomyelia<sup>149</sup>. When symptomatic, HBs of the CNS cause disruption of neurological functions, or symptoms due to raised intracranial pressure, often caused by the adjoining cyst. Magnetic resonance imaging (MRI) enables the detection of even incipient asymptomatic HBs of the CNS in VHL.

Retinal HB is the first manifestation in about half of the VHL patients<sup>118</sup>, and is usually bilateral and multifocal, or becomes so over the years<sup>105,118</sup>. The mean age at presentation is 25 years<sup>118,118,174</sup> and the estimated cumulative probability to develop retinal HBs exceeds 70% by the age of 60 years<sup>108</sup>. There is no general influence of germline mutation on the severity of retinal HBs<sup>170</sup>.

VHL occurs in only 2% of RCC patients, whereas in VHL patients RCC develops in up to 45% of the patients<sup>62,63,121</sup>. Compared to sporadic RCC, in VHL patients RCC is characterized by appearing 25 years earlier (i.e. at the average age of 35 years), an association with renal cysts, multifocal and bilateral tumors, and low grade

histology<sup>72,121,135</sup>. The incidence of metastatic disease for VHL patients with RCC has been reported to be 20%<sup>114</sup>. The distribution of metastases is similar to that of sporadic cases of RCC including liver, lung and bones. Abdominal computed tomography (CT) with contrast, using 5 mm contiguous sections represents preferable radiographic assessment of the kidney<sup>32,65</sup>. CT helps in differentiating simple cysts (smooth borders and a homogeneous attenuation similar to water) and complex cysts (mostly cystic but containing some solid elements) from solid masses (attenuation higher than water and enhanced with contrast)<sup>65</sup>. Renal ultrasonography (US) is a useful screening method, but does not offer comparable anatomic detail<sup>65</sup>. For patients with advanced renal insufficiency or contrast allergy, MRI before and after gadolinium yields equivalent results to CT. Renal arteriography is important for surgical planning when a partial nephrectomy is anticipated<sup>65</sup>. Earlier, nephrectomies were often performed, but lately nephron-sparing surgery (lesionectomy or partial nephrectomy), whenever possible, has been recommended as primary treatment<sup>65</sup>. The prognosis of RCC is better in VHL patients than in sporadic ones, and metastases are claimed to appear in VHL only after the primary tumor exceeds 7 cm in diameter<sup>121</sup>. It has been proposed that single tumors should be excised already when their diameter is 2-3 cm<sup>100</sup>.

Pheochromocytomas are catecholamine-producing tumors of the adrenal medulla<sup>5,6,27,28,48</sup> occurring in 20-35% of VHL patients at the median age of 30 years<sup>118,138</sup>. About 20% of all pheochromocytomas are related to VHL<sup>116</sup>. In VHL, these tumors tend to be bilateral and multiple, but they are rarely malignant<sup>116,138</sup>. Pheochromocytomas can be located within or outside the adrenals<sup>116</sup>. Presenting symptoms are palpitations, headache, sweating attacks and hypertension. The diagnosis is based on imaging of the adrenals by US, CT or MRI, and supported by measurement of plasma and urine catecholamines. In extra adrenal lesions, scintigraphy with <sup>123</sup>I or <sup>131</sup>I-labeled metaiodobenzylguanetidine is usually diagnostic<sup>116,118</sup>. Symptomatic tumors should be enucleated rather than treated by adrenalectomy<sup>118,122</sup>.

Pancreatic adenocarcinoma and malignant islet cell tumors occur in VHL<sup>92</sup> 108,118,138. Therefore, VHL patients should be followed regularly with abdominal CT or

MRI scans to detect asymptomatic lesions so that they could be operated before the appearance of metastases.

VHL predisposes to cysts in the kidneys, pancreas and liver<sup>29,31,32,118</sup>. These cysts tend to be multiple, e.g. in the kidneys bilateral and slowly growing<sup>32</sup>, and they require follow-up because of the possible adjoining malignancy<sup>135</sup>. Renal cysts are usually asymptomatic and do not require treatment as such. In polycystic kidney disease<sup>15</sup>, another autosomal dominant disease, the number of cysts usually exceeds that detected in VHL, and there are no adjoining malignancies. VHL patients with large pancreatic cysts may have mild discomfort, but bile duct obstruction, pancreatitis, and hormonal insufficiency requiring surgical intervention are rarely reported<sup>9,54</sup>.

Epididymal cystadenomas have been observed in 3% of VHL patients<sup>30,118</sup>, and in bilateral cases they may impair fertility. After manual examination or US, they may be excised, but usually this does not improve fertility<sup>40,118,175</sup>. Endolymphatic sac tumors (ELST) are destructive neoplasms located in the posterior wall of the petrous bone in the region of the vestibular aqueduct<sup>82,109</sup>. The usual symptoms are tinnitus, hearing loss and vertigo. If left untreated, ELSTs usually progress and cause total deafness<sup>109</sup>. Complete surgical excision, if possible, is recommended and may preserve hearing<sup>109</sup>.

#### *Prognosis of VHL*

The mean age at death in VHL is 40 to 50 years<sup>115</sup>. RCC has exceeded HBs of the CNS as the primary cause of death (50 and 30%, respectively) due to advances in the microsurgery of HBs of the CNS<sup>105</sup>. About 5% of VHL patients die from endogenous catecholamine intoxication caused by pheochromocytomas<sup>116</sup>, and less than 5% from pancreatic carcinoma<sup>115</sup>.

### **3. Problems of treatment in VHL**

#### *Hemangioblastomas of the CNS*

In VHL, microsurgical treatment of multiple HBs often fails in the long run. Removed tumors tend to recur<sup>39</sup> and new ones develop; some are symptomatic and others

incidental. It is often difficult to decide which tumors should be removed, and operative risks should be weighed against the natural course. Furthermore, in VHL, more often than in sporadic cases, HBs are located in the brainstem and spinal cord<sup>138</sup> increasing the risk of morbidity and mortality related to microsurgery of these lesions. The operative mortality for a cerebellar cystic tumor is less than 2%, but it increases considerably for a large solid lesion intrinsic to the caudal brainstem<sup>137</sup>. Stereotactic radiotherapy may offer a safer means to treat HBs in eloquent brain areas, but overlapping fields in patients with multiple HBs may pose a problem of radiation injury to the adjacent brain.

#### *Hemangioblastomas of the retina*

In VHL, the appearance of new and multiple HBs of the retina typically threaten vision<sup>118,138,170,174</sup>. All retinal HBs, even small and asymptomatic, should be treated with laser or cryocoagulation to prevent loss of vision<sup>174</sup>. However, in papillary or macular HBs, coagulation may cause a central visual field defect, and treatment is not advised until exudation develops<sup>123,174</sup>. The feeder vessels and exudates do not require direct treatment, their presence is secondary to the HB, and the treatment of feeders may cause hemorrhage<sup>123,155</sup>.

Laser coagulation often requires multiple sessions to scar the entire HB<sup>155,174</sup>. A single session may be adequate if the HB is very small (0.5 DD; 1 DD ~ 1.5 mm)<sup>155,174</sup>. The success of treatment can be determined about two months after treatment<sup>155</sup>, attenuation of the feeders and absence of fluorescein leakage from the HB are suggestive of a good result<sup>155</sup>. In the cryocoagulation of larger lesions, the cryoprobe is located directly over the HB transsclerally in indirect ophthalmoscopy. An initial treatment temperature of -50°C is recommended to decrease the risk of hemorrhage when the temperature is lowered during the same session to the range of -60 to -80°C<sup>123,155</sup>. Treatment at a temperature higher than -80°C avoids excessive uveitis and exudation. If the HB shows little or no whitening during freezing, the thermal barrier of subretinal fluid or exudate is too great for cryosurgery to be effective<sup>155</sup>. If freezing produces at least partial whitening of the HB, the freezing should be repeated twice<sup>155</sup>. If the feeders have not attenuated by two months after cryotherapy, the treatment should be repeated. At six months after therapy, the HB should appear as a pigmented scar, the exudate surrounding

the HB should have diminished or disappeared, the feeders should be atrophic, and the macula dry<sup>155</sup>. Brachytherapy with episcleral ruthenium-106 plaques has also been used to treat large (>2 DD) lesions<sup>89</sup>.

Late recurrences may develop mainly due to incomplete primary destruction of the HB, but in VHL new tumors may be mistaken for recurrences<sup>4</sup>. Retinal detachment without vitreous traction may be treated by scleral encircling procedures. Macular preretinal fibrosis, vitreous hemorrhage or retinal detachment threatening the macula may necessitate vitreoretinal surgery<sup>91,103,110</sup> which has improved the prognosis of vision in eyes with large HBs. Cataract and neovascular glaucoma following total retinal detachment are late complications of the disease with a poor prognosis<sup>123</sup>. Enucleation may become mandatory in the case of a blind and painful eye<sup>174</sup>.

#### *Renal cell carcinoma (RCC)*

VHL patients tend to develop multiple bilateral RCCs threatening renal function and life<sup>115,118</sup>. The decision to proceed with nephron-sparing surgery or radical nephrectomy depends on the extent of the disease<sup>65</sup>. Nephron-sparing surgery may be effective for patients with localized RCC, but most will have local recurrences. There are also patients in whom nephron-sparing surgery is not feasible and bilateral nephrectomy has to be performed.

In a series of 65 VHL patients with RCC treated with radical nephrectomy or nephron-sparing surgery, the RCC-specific survival rate at 5 and 10 years was 95 and 77%, respectively<sup>157</sup>. However, altogether 23% of the patients developed end-stage renal failure<sup>157</sup>, and at this stage, management options include dialysis or renal transplantation.

In a multicenter series of 28 VHL patients with end stage RCC and renal transplantation<sup>65,66</sup>, the average age at diagnosis of RCC was 31 years and at transplantation 37 years. The mean duration of dialysis before transplantation was 28 months (range 2-84 months). Twenty-three patients (82%) were alive without evidence of recurrent disease at a mean of 51 months after transplantation. The need for a surveillance interval during dialysis, in order to prevent the early development of metastatic disease after transplantation is important. According to a review of 56 patients in whom incidental RCC had been removed at variable times before transplantation<sup>132</sup>, patients with low

stage, asymptomatic RCC did not need a surveillance interval before transplantation. However, patients with symptomatic higher stage RCC have a greater risk of recurrent disease, and a surveillance interval of at least two years is recommended before transplantation<sup>132</sup>. When a VHL patient is considered for renal transplantation, VHL exclusion in living related donors is mandatory.

#### **4. Novel treatment methods**

##### *Stereotactic radiotherapy*

Stereotactic radiotherapy (SR) is a non-invasive and well-tolerated means to shrink or control well-delineated intracranial neoplasms and to occlude AVMs<sup>158,160</sup>. For single session treatment ('radiosurgery') the targets should be small (< 30 mm) because of a dose-volume-dependent risk of delayed radiation injury, but fractionation using a relocatable head frame allows larger volumes. HB and hemangiopericytoma (HPC) are highly vascular, sharply circumscribed solid tumors that dislocate rather than infiltrate the adjacent brain. HPC is semi-malignant and possibly therefore its response is dramatic and rather rapid: most of 11 meningeal HPCs in five patients treated with the gamma knife (GK) shrank within 6 to 10 months after an average margin dose of 15 (range 12 - 18) Grays (Gy)<sup>34</sup>. The only morbidity was a partial visual-field defect in one patient. AVMs, highly vascular non-neoplastic congenital lesions of the brain, respond by slow obliteration of the nidus within one to three years, suggesting that the vessel walls of AVMs are prone to a specific mechanism of delayed radiation injury that finally occludes them<sup>59,101,158,159</sup>. In a series of 227 AVMs<sup>101</sup>, treated in one session with the GK with an average margin dose of 21 (range 12 - 27) Gy, the 2-year obliteration rate according to volume was 100% (< 1 cm<sup>3</sup>), 85% (1-4 cm<sup>3</sup>) and 58% (> 4 cm<sup>3</sup>). Symptoms attributable to radiation injury developed in 6% of the patients at a mean interval of 10 months. Radiosurgery (RS) seems to reduce the risk of rebleeding in cavernous hemangiomas<sup>88</sup>, a congenital vascular malformation receiving less arterial supply than AVMs, but the overall role of RS vs. microsurgery in the treatment of these lesions remains to be elucidated<sup>99,160</sup>.

HBs should be ideal targets for RS because they are usually small, rounded, well-delineated and highly vascular, and in VHL patients they are often multiple<sup>117,118,138</sup>.

They receive an intense arterial supply from the adjacent brain tissue, and one might expect obliteration of these feeding vessels. In order to be superior to microsurgery, RS of HBs should be safer in eloquent areas in terms of radiation injury, it should shrink the tumor or at least stop its growth in the long run, and prevent expansion or formation of cysts. RS is apparently superior in terms of hospital stay and immediate costs, but years of follow-up and possible surgery later may result in a different total.

### *Antiangiogenic therapy*

Angiogenesis is fundamental to reproduction, development and repair<sup>57</sup>. Pathological angiogenesis with unabated blood vessel growth sustains progression of many neoplastic and non-neoplastic diseases<sup>57</sup>. Antiangiogenic tumor therapy is targeted at small foci of migrating and proliferating endothelial cells in capillaries at sites of angiogenesis<sup>56,143</sup>, an attempt to inhibit tumor growth<sup>86,90,127,128</sup>.

Interferon-alpha (IFN $\alpha$ ) with immunomodulatory, antiproliferative and antiangiogenic activities, has an established role in cancer therapy<sup>71,154</sup>. In hairy cell leukemia, patients treated with IFN $\alpha$  have a 89% survival rate at five years, in comparison to 34% in patients without any therapy<sup>58</sup>. In life-threatening hemangiomas of the liver and facial areas in children, the response to long-term IFN $\alpha$  treatment at a high dosage is often favorable, as most lesions shrink markedly by 12 months when treated with  $3 \times 10^6$  International Units (IU)/m<sup>2</sup> daily<sup>51</sup>. In metastatic cutaneous melanomas and RCCs, better response rates and prolonged survival are achieved with treatment regimens containing IFN $\alpha$  as compared to regimens without it<sup>71</sup>.

In general, IFN $\alpha$  is well tolerated. Its side-effects are dose-dependent, usually being transient acute mild flu-like symptoms after injections<sup>85,134</sup>. Subacute and chronic adverse effects include fatigue, leukopenia, and less commonly, thrombocytopenia and anemia<sup>85,134,165</sup>. Pulmonary and cardiac toxic effects have been encountered after weeks or months of therapy<sup>173</sup>, but severe cardiomyopathy as well as fatal multiorgan failures have been described within the first few days of therapy<sup>20,35,136</sup>. In long-term use and with higher doses, neurotoxicity with gait disorders, dizziness, and memory problems have been described<sup>42,173</sup>. Notably, patients affected by depression during long-term treatment

are at increased risk of becoming manic if IFN $\alpha$  treatment is withdrawn abruptly<sup>19</sup>. The mechanism of IFN $\alpha$ -linked mood disorders is unknown.

In VHL, HBs of the CNS and retina could be ideal targets for systemic antiangiogenic therapy because they are highly vascular, often multiple, and located in eloquent brain areas with increased microsurgical and radiosurgical risks, and VEGF may have a role in their pathogenesis<sup>64,70,162</sup>. There are no published data on the effect of IFN $\alpha$  in the treatment or prevention of HBs of the CNS and retina.

## **AIMS OF THE STUDY**

This study was aimed to answer the following questions:

I HB of the CNS: VHL prevalence and long-term prognosis?

II HB of the retina: VHL prevalence and long-term prognosis of vision?

III HB of the CNS: impact of stereotactic radiosurgery?

IV Asymptomatic HBs of the CNS and retina: impact of 12-month treatment with IFN $\alpha$ 2a?

## **PATIENTS, TUMORS, AND METHODS**

### **1. Patient Series I-IV**

#### *VHL prevalence and long-term prognosis of 110 patients with HBs of the CNS (I)*

The files of the Department of Neurosurgery, Helsinki University Central Hospital (HUCH), a unit practicing the so-called population-based responsibility service system, revealed 110 consecutive HB patients fulfilling the following criteria: primary operation for HB(s) of the CNS between 1953 and 1993, histologic verification of the solid part, and HB ascertained at histological re-examination by a neuropathologist.

All available clinical data were collected to find out the occurrence of VHL manifestations in these 110 HB patients (50 men, 60 women). The records of the Department of Neurosurgery and all other hospitals involved were surveyed for clinical, imaging, operative and autopsy evidence of VHL. The addresses and the death certificates of the patients were obtained from the Population Register Center (PRC) of Finland and Statistics Finland. A detailed inquiry on all their illnesses, hospital admissions and operations was sent to patients before the follow-up examination. The follow-up time started at the date of the primary operation and ended at death (49/110 patients) or on August 31, 1998. No patient was lost to follow-up.

A detailed clinical examination to reveal signs of VHL was performed between 1991 and 1998 in 61 of the 66 live patients. This included family history for VHL, a physical and neurological examination, ophthalmologic examination including indirect ophthalmoscopy and Goldmann 3-mirror contact lens fundus examination, enhanced MRI (1.0 T) of the head and upper cervical spine, and enhanced CT of the upper abdomen (kidneys, adrenals, liver and pancreas).

#### *VHL prevalence and long-term prognosis of vision in 36 patients with HBs of the retina (II)*

According to the hospital files altogether 36 consecutive patients with retinal HB(s) were treated at the Department of Ophthalmology, HUCH, a unit also based on the population responsibility service system, between January 1, 1974, and June 30, 1998, and these 36 patients were included in the study.

The files of the Department of Ophthalmology, and all other hospitals involved were surveyed for clinical, imaging, operative and autopsy evidence of VHL in the 36 patients (10 men, 26 women). The addresses and the death certificates of the patients were obtained from the PRC and Statistics Finland. The follow-up time started at the detection of retinal HB(s) and ended at death (6/36), emigration (1/36), or on December 31, 1998. No patient was lost to follow-up.

All living patients were invited to a multidisciplinary follow-up evaluation between 1991 and 1998. Of the 36 patients, 31 (86%) were able to attend the detailed clinical examinations to reveal signs of VHL, including family history for VHL, neurological examination, enhanced MRI (1.0 T) of the brain and the spinal cord, enhanced CT of the upper abdomen (kidneys, adrenals, liver and pancreas). Complete ophthalmologic examination included indirect ophthalmoscopy and Goldmann 3-mirror contact lens fundus examination. In the remaining five patients (one had emigrated, three had died and one refused to participate), all available ophthalmologic and other relevant data from other centers were reviewed.

#### *Gamma knife radiosurgery in 11 HBs of the CNS (III)*

The database of the Gamma Knife Center at the Department of Neurosurgery, Karolinska Hospital, Stockholm, Sweden, revealed 10 consecutive patients treated for HB(s) of the CNS with the GK between April 11, 1978, and November 30, 1994. They account for 0.4% of the 2796 patients treated in the same period. There were five men and five women (median age 48 years). The native countries were Sweden (4), Germany (2), United Kingdom (1), Belgium (1), USA (1) and Greece (1). Four of the ten patients had a clear clinical manifestation of VHL including multiple intracranial HBs, retinal HBs, internal organ cysts or family history. Three VHL patients had multiple intracranial HBs at the time of RS. No linkage or mutation analyses were performed.

Eleven HBs (nine cerebellar, one mesencephalic and one suprasellar) were treated with the GK. Six of the 11 tumors were histologically verified as HBs, five of them before and one after RS, and four tumors occurred in VHL patients giving indirect evidence of histology. Histological sections were not reviewed. In one tumor, the diagnosis was based on radiological findings only. At the time of RS, six HBs were solid and five were cystic. Pretreatment angiograms, CT or MRI scans of nine HBs were re-examined, and the median of the largest diameters was 14 (range 6 - 43) mm. Symptoms attributable to the

HBs intended for RS were present in five patients, and in the remaining five patients these HBs were incidental. None of the eleven HBs had been embolized or irradiated before, but four HBs were residuals or recurrences from previous surgery.

The first three HB patients were treated with the GK prototype Mark II, used from 1975 to 1988, and the next seven patients with the Leksell gamma knife Type B, used since 1988. Dose planning was based on angiography in two patients, on CT in six patients, and on MRI in two patients. The margin dose was reduced in 1990 reflecting a general tendency to lower doses, and the six HBs before 1990 received a median of 25 (range 20 - 35) Gy while the next five HBs received a median of 10 (range 5 - 19) Gy.

All available data on the clinical course of the ten patients and their neuroradiological studies after RS were gathered from the files of the Karolinska Hospital and the referring physicians and hospitals. For the first patient no medical records after RS were obtained, and the follow-up information was given by a relative. Medical records were available for the next nine patients until death or the last follow-up date in 1994 or 1995. In eight tumors, the response until the last follow-up or subsequent surgical removal was evaluated from the original radiological images, whereas in two HBs the response could be assessed from the radiological reports only. The volumes (total area of the slices x slice thickness) of the tumors and cysts were calculated using a computerized planimeter.

#### *IFN $\alpha$ 2a treatment in 18 HBs of the CNS and retina (IV)*

Three VHL patients with 14 small, asymptomatic HBs of the CNS and three asymptomatic retinal HBs, and one non-VHL patient with one HB of the CNS were included in the study. A base-line work-up consisted of a physical and neurological examination, obtaining family history for VHL, complete ophthalmologic examination including indirect ophthalmoscopy and Goldmann 3-mirror contact lens fundus examination and FA in patients with retinal HBs, enhanced high-resolution MRI of the head and the spine, and enhanced CT of the kidneys, adrenals, liver and pancreas.

Recombinant human IFN $\alpha$ 2a (Roceron-A®, Roche, Switzerland) was injected subcutaneously (s.c.) by the patients themselves at a dose of  $3 \times 10^6$  International Units (IU) three times per week for 12 months. When necessary, anti-inflammatory drugs were administered to prevent shivering and other flu-like symptoms after the injections. Side-effects were recorded at follow-up examinations performed at few-month intervals in a

hospital out-patient department. The blood cell counts and liver transaminases were monitored. The WHO classification<sup>112</sup> was used in the grading of toxicity.

The response of the HBs of the CNS and visceral cysts to treatment was judged by comparing the sizes of the lesions (maximal diameter in mm) at three, 13, and 21-22 months after the start of the therapy. The diameters of the retinal HBs were measured from retinal photographs and FAs.

To monitor the systemic effects of the treatment, the serum levels of hemoglobin, VEGF and EPO were measured before the treatment and at three and nine months after the initiation of the therapy. S-VEGF concentrations were determined as S-VEGF immunoreactivity, using a quantitative sandwich enzyme immunoassay technique essentially as described earlier (Quantikine R, R&D Systems, Minneapolis, MN)<sup>148</sup>. The serum levels of EPO were measured as S-EPO immunoreactivity (Human EPO IVD, R&D Systems, Minneapolis, MN) essentially similarly to S-VEGF measurement.

## **2. Histological and proliferation analysis (Patient Series I)**

The histological verification of HBs of the CNS was performed by a neuropathologist according to the WHO classification of tumors<sup>17,87</sup>. Proliferation by MIB-1 (Ki-67) labeling could be studied in 39 of the primary 87 HBs operated on between 1968 and 1993, and in 11 recurrences and second tumors of these patients. Briefly, monoclonal antibody MIB-1 (IgG, Immunotech, Marseille, France) was used on deparaffinized and rehydrated tissue sections. The sections were treated in a microwave oven and the primary antibody was visualized with a streptavidin-biotin technique (Zymed Laboratories, CA)<sup>146</sup>. The proliferation index (MIB-1 index) is the percentage of immunopositive tumor cell nuclei among at least 500 neoplastic nuclei<sup>69</sup>.

## **3. Finnish Cancer Registry (Patient Series I-II)**

The population-based nationwide Finnish Cancer Registry (FCR) has functioned since 1953. All hospitals, health care centers, physicians, and pathological laboratories are requested to notify the FCR of all cancer cases (benign and malignant CNS tumors included) that come to their attention, and the FCR also receives information of all death

certificates with a cancer diagnosis: over 99% of the 63 722 solid tumors diagnosed in Finland between 1985 to 1988 were recorded at the FCR<sup>166</sup>. Furthermore, everybody living in Finland has had an 11-digit personal identification code since 1967 allowing complete follow-up of every person for death and emigration, and also linking files between different registries.

#### **4. Pedigree analysis (Patient Series I-II)**

*In Patient Series I*, altogether 35 out of the 110 HB patients had at least some data suggestive of VHL. Detailed pedigrees with first and second degree relatives were constructed for them by interviewing the patients or using the files of the PRC and the parish records. The 35 patients with their 471 relatives were linked with the files of FCR to find VHL-related neoplasms (HB of the CNS, RCC, pancreatic carcinoma, pheochromocytoma). *In Patient Series II*, detailed pedigrees including first and second degree relatives were constructed for all 36 patients in the series. These 36 patients and their 995 relatives were also linked with the files of FCR to find VHL-related neoplasms.

#### **5. Mutation analysis (Patient Series I-II)**

*In Patient Series I*, germline mutations of the VHL gene were analyzed by direct sequencing from peripheral blood samples of all live patients with clinically definite VHL (4/14), suspect patients with HB and internal organ cyst(s) (11/13), and also in 25 apparently sporadic HB patients. *In Patient Series II*, germline mutations of the VHL gene were studied by direct sequencing in 29 of the 36 patients. In both series, high molecular weight DNA was extracted from peripheral blood leukocytes by the QiA Amp Blood kit (QiAGEN Ltd., Cambridge, UK). The three exons of the VHL gene (coding region of 852 nucleotides) were sequenced, including the exon splice sites. The primers and the PCR conditions (with slight modification) were as described elsewhere<sup>25</sup>. We also used a reverse primer for the exon 1, SS1, 5'GCGGTAGAGGGGCTTCAGACCGTG-3'. PCR products were purified with the QiA quick PCR purification kit (Qiagen, Hilden, Germany), and the sequencing reactions were done using the ABI PRISM DYE

Terminator sequencing kit (Perkin-Elmer Applied Biosystems Division, Foster City, CA); the products were analyzed on the ABI 373 A sequencer. Both strands were sequenced.

## **6. VHL criteria (Patient Series I-IV)**

Diagnosis of VHL is based on mutation analysis<sup>94,161</sup>, and clinical manifestations during long-term follow-up<sup>31,108,111,114</sup>. According to the traditional VHL criteria<sup>31,108,111,114</sup>, also patients with multiple HBs of the CNS or retina as the only manifestations have VHL. In our study, a patient with HB(s) of the CNS or retina was classified as having (1) definite VHL if the patient had a germline mutation or family history of VHL or other VHL-related neoplasms (RCC, pancreatic carcinoma, pheochromocytoma). A patient with no family history and no other VHL-related neoplasms had (2) suspect VHL if the patient had either (a) one HB of the CNS or retina and visceral cysts or (b) more than one retinal HB.

## **7. Statistical methods (Patient Series I-III)**

Median and range were used to describe distributions, and Mann-Whitney or Kruskal-Wallis tests to compare groups. Fisher's exact test (2-tail) and Yates' corrected Chi-square test were used to assess differences in frequencies in the different patient groups.

## RESULTS AND DISCUSSION

### 1. VHL prevalence and long-term prognosis of 110 patients with HBs of the CNS (I)

#### *The prevalence of VHL in patients with HB(s) of the CNS*

All available clinical data gathered during the median follow-up time of 14 (range 0.3-36) years together with a detailed clinical examination (61/110 patients), family history (93/110 patients), detailed pedigree (35/110 patients), mutation analysis (40/110 patients) and linkage to the files of the FCR (35 HB patients and 471 relatives) led to the distinction of three different patient groups: (a) 14 VHL patients (13%); (b) 13 patients with a single HB and visceral cyst(s) but no other VHL manifestations; and (c) 93 apparently sporadic HB patients. The linkage of HB patients and their relatives to the FCR files to find out VHL-related tumors did not disclose new VHL families.

The mutation analysis could be performed in four VHL patients, in 11 patients with a single HB and visceral cyst(s), and in 25 patients with a single HB. We used direct sequencing of the VHL gene which is more sensitive than SSCP (Single Strand Conformation Polymorphism) which detects 50% of VHL mutations<sup>25,94,178</sup>. We found a germline mutation in exon 1 in two of the four VHL patients studied (278 G to C and 293 A to G), but in none of the other 36 patients. Both mutations cause an aminoacid missense substitution (Gly - Ala and Tyr - Cys, respectively), and are known to be associated with pheochromocytomas<sup>26</sup>, which appeared in the family of one VHL patient. Recent data suggest that with combined techniques (quantitative Southern blotting, Southern blotting, FISH, and complete sequencing of the gene) virtually all mutation carriers, also those with deletions, could be identified<sup>129,161</sup>.

The prevalence of at least 13% of VHL in this unselected and population-based series of 110 patients operated on for HBs of the CNS appears to be an underestimation when compared to recent studies<sup>12,61,107,117,138,140</sup>, showing prevalences of up to 40%. Our series was retrospective, spanning over four decades, and characterized by high operative mortality in the early years. On the other hand, the follow-up time was long and all available data were collected to detect the cases of VHL: 61 live patients were studied clinically in detail, eight patients had clearly developed VHL, in 17 patients autopsy

excluded VHL, and 12 patients reached the age of 65 years or more without signs of VHL. This left 13 patients with data insufficient to rule out VHL.

#### *Characteristics of VHL patients*

Of the unrelated 14 VHL patients (five men, nine women), six (43%) had a family history of VHL, and eight apparently had a new mutation, a proportion corresponding to the literature<sup>104</sup>. The frequency of VHL in patients operated on for HB(s) of the CNS was 31% (4/13) before the age of 25, 19% (9/48) between 25 and 45 years, and only 2% (1/49) after 45 years. In 11 of the 14 VHL patients (79%), HB(s) of the CNS was the first manifestation of the disease. Multiple HBs of the CNS were detected in 10 patients and a single one in four, retinal HBs in eight patients (5/8 bilateral), RCC in 10 patients (6/10 bilateral), and pheochromocytoma in two patients (one bilateral), pancreatic carcinoma in one patient, bilateral renal cysts in eight patients, and pancreatic cysts in three patients. No liver cysts were encountered. In the 14 VHL patients, the median age at the first operation for HB(s) of the CNS was 33 (18-50) years, significantly ( $p=0.005$ ) less than the 45 (16-79) years in the 96 non-VHL patients (45 men, 51 women) in concordance with earlier studies<sup>118,138</sup>. The median age at the detection of retinal HB(s) was 39 (range 19-65) years in contrast to the 25 years in VHL-based series<sup>118,170</sup>. RCC was detected in 10 VHL (67%) patients (two at autopsy) at the median age of 43 (range 26-57) years, somewhat later than the 33 years in a recent series<sup>118</sup>, and at a median interval of 11 (range 0.1-25) years from the first operation for HB(s).

#### *HB of the CNS*

The site of the HB(s) differed between VHL and non-VHL patients: brainstem or spinal HB(s) occurred at some stage in half of the 14 VHL patients, whereas only 5% (5/96) and 4% (4/96) of the non-VHL patients had a single HB in either of these two locations, in concordance with the literature<sup>53,79,107,138,140</sup>. Brainstem and spinal cord locations contribute to the increased management morbidity of HBs in VHL. Supratentorial HBs are rare<sup>138</sup>. In our series, two of the 14 (14%) VHL patients and three of the 96 (3%) non-VHL patients had a supratentorial HB. Of the 110 patients, 14 died within three months after the primary operation, mostly in the early years. During the last

10 years, there was only one (4 %) operative death after partial removal of a brainstem HB out of the 26 operations performed.

HB is a slowly growing tumor. There is a general impression that VHL-associated HBs grow faster than sporadic HBs, but this is difficult to prove because no volume growth data are available for non-VHL tumors. Time to recurrence in the original operation area after seemingly complete removal tells something about the volume growth rate but de novo tumors may be mistaken for recurrences in VHL patients. HB is a microsurgically curable tumor, but the risk of late recurrences may be higher than generally expected. Recurrence of an HB in the original operation area developed in four of the 10 VHL patients whose primary operation was considered to be radical, at two, 16, 21 and 25 years (median 19 years), and in nine of the 74 non-VHL patients at a median of 11 (range 3-35) years. The time to recurrence did not differ between VHL and non-VHL patients, suggesting a similar growth rate of HBs in both groups, in agreement with low MIB-1 labeling indices (0.3% for 9 VHL tumors vs. 0.2% for 41 non-VHL tumors). In a previous series of 26 HB patients operated on between 1974 and 1986<sup>39</sup>, seven patients developed a recurrence at a mean interval of seven years after total removal. There was no distinction of VHL-related HBs. The mean MIB-1 index was 2.8%, higher than in our series, possibly due to differences in staining and quantitation protocols. In our series, seven of the 13 patients with recurrences died of recurrence at a median of 20 (range 3-35) years after the primary complete removal of the tumor. Late recurrences are a challenge in terms of detection and microsurgery in elderly persons.

#### *HB of the retina*

We performed a detailed ophthalmologic examination of 60 of the 110 patients, and another 35 patients had had ophthalmoscopy earlier during the follow-up. No ophthalmologic data were available on 15 patients. Retinal HBs were detected in eight patients, and only two of them had retinal HBs as their first VHL manifestation. In larger VHL series, retinal HB is the first manifestation in about half of the patients<sup>105,118</sup>. In our series, four VHL patients had visual disturbances, and four were asymptomatic at detection. When a patient had HBs both in the CNS and the retina, there were always other VHL manifestations present.

### *Lesions suggestive of VHL*

In 11 of the 14 VHL patients, the upper abdomen was studied by CT, US, surgery or autopsy, and cysts were found in eight patients. None of the cysts were the sole indication for surgical intervention. There were 13 patients with a single HB and asymptomatic cyst(s) of internal organs. The median age of 56 years at the first HB operation, the lack of other VHL-associated manifestations, negative family history, and no germline mutations of the VHL gene (11 patients studied) together suggest that the internal organ cyst(s) in these 13 patients were incidental findings. The cyst(s) occurred in the kidney(s) in 10 patients (three bilateral), in the liver in four patients, in the pancreas in two patients, and in the spleen in one patient. In our series, the abdominal organs of 60 patients, regarded to be free of VHL, were imaged by CT (54 patients) or US (six patients), and incidental cysts were found in 17% (10/60) in the kidneys, 7% in the liver (4/60), and 3% (2/60) in the pancreas. Visceral cysts in patients with a single HB of the CNS may suggest VHL. In our series, however, 13 (14%) HB patients who were considered as free of VHL had visceral cysts. Characteristically, they had fewer cysts per organ and patient than did the VHL patients. The occurrence of non-VHL cysts in our series corresponds to that of the general population<sup>18,74,95,168</sup>.

The lesions detected in VHL may also occur incidentally in otherwise healthy subjects, but typically at an older age than in VHL patients<sup>118,138</sup>. Multiple HBs of the CNS are considered as a classical sign of VHL. In our series, one non-VHL patient (1%) had two HB nodules in the same cyst wall at the primary removal. A negative family history and no germline mutation together with the lack of other VHL manifestations during the long follow-up suggest that this patient did not have VHL. Multiple HBs may still represent mosaicism or segmental VHL, the negative family history explained by a mosaicism or no VHL gene defect in the germ cells. Neurofibromatosis type 2 (NF2), another dominantly inherited syndrome with a defective NF2 tumor suppressive gene predisposes to multiple schwannomas and meningiomas, but the defective NF2 gene may also cause sporadic schwannomas and meningiomas<sup>52,78,102,152,153</sup>. In the schwannoma population, 95% of the patients have single and obviously sporadic tumors, 2% have multiple but without classical NF2, and in 3% the tumors are related to NF2<sup>3</sup>.

### *Long-term survival of patients with HB(s) of the CNS*

In our series, 12 of the 14 VHL patients survived at least two years after the primary HB operation. The median follow-up time for these 12 patients was 16 (range 4-26) years, and during the follow-up nine of them died at a median age of 47 (range 26-66) years. All died of the disease, five of RCC at a median of 49 (range 26-66) years, three of HB(s) at a median age of 47 (range 46-51) years, and one of pancreatic carcinoma at 45 years. 70 of the 96 non-VHL patients survived more than two years after the primary radical HB removal. During the median follow-up time of 16 (range 2-36) years, 18 patients died at the median age of 65 (range 51-81) years. There were six deaths due to recurrence of the HB in the original operation area after a median of 15 (range 3-35) years at the median age of 66 (range 55-81) years, and 12 non-related deaths at the median of 65 (range 51-77) years.

The average life-expectancy of VHL patients is 40 to 50 years<sup>115</sup>. At present RCC is the leading cause of death of VHL patients<sup>105</sup>, and it was also a major cause of mortality in our series. In a recent series of 65 VHL patients with RCC treated with radical nephrectomy or nephron-sparing surgery, the RCC specific survival rate at five and 10 years was 95 and 77%, respectively, but 23% of the patients developed end-stage renal failure<sup>157</sup>. Renal transplantation is an option to treat anephric VHL patients. The results from a series of 28 patients suggested that immunosuppression would not enhance the growth of existing tumors<sup>65</sup>. Further studies with long follow-up are needed to show whether prolonged immunosuppression increases the risk of second malignancies in VHL patients with renal transplants<sup>132</sup>. These aspects are crucial when deciding whether prophylactic bilateral nephrectomy with renal transplantation is offered as a life-saving treatment for VHL patients. Another possibility would be to develop a specific drug therapy against HBs and RCCs, e.g. relating to angiogenesis in both tumors.

### *Early detection of VHL lesions*

All patients with HB(s) of the CNS should be screened for VHL by MRI of the brain and spinal cord, ophthalmoscopy, abdominal CT or MRI, and by obtaining the family history and performing VHL germline mutation analysis<sup>61</sup>. The children of a patient with a VHL gene defect have a 50% risk of getting the disease, and they should be offered the possibility of predictive germline mutation testing to avoid laborious and expensive long-

term clinical screening. Furthermore, it was recently shown that patients with mutations causing truncation or deletion of the VHL protein developed more often multiple HBs of the CNS and had more often multiple operations than patients with mutations predicted to produce a full length VHL protein<sup>61</sup>. This suggests that truncating mutations induce a more severe disease and thereby might influence the clinical management<sup>61</sup>. Early detection of incidental HB(s) of the CNS may be more favorable at least in terms of radiosurgery<sup>23,125</sup>. When retinal HBs are small and asymptomatic they are easier to treat with laser or cryocoagulation, and the prognosis of vision is better<sup>174</sup>. Early detection probably ensures also a better prognosis of RCC<sup>65,120,157</sup>.

## **2. VHL prevalence and long-term prognosis of vision in 36 patients with HBs of the retina (II)**

### *Distinction of VHL patients among patients with retinal HB(s)*

All previous clinical data, and the present data obtained by a detailed clinical and radiological examination (31/36 patients), pedigree analysis (36/36 patients), germline mutation analysis (29/36 patients), and linkage of the 36 patients and their 995 first and second degree relatives (a median of 28 relatives per patient) to the files of the FCR led to the distinction of three patient groups: 1) 11 definite VHL patients (30%); 2) 10 suspect VHL patients (28%) with multiple retinal HBs or with a single retinal HB and visceral cysts but no other VHL-related neoplasms and no family history; and 3) 15 non-VHL patients (42%) with a single retinal HB. The linkage to the FCR files to find VHL-related tumors did not disclose any VHL patients or families not known before. The germline mutation analysis by direct sequencing was possible in eight of the 11 clinically definite VHL patients and disclosed a mutation in six (75%): three in exon 1 (277 G to C causing amino-acid missense substitution Arg to Pro; 278 G to C causing substitution Gly to Ala; and 293 A to G causing substitution Tyr to Cys) and three (two patients from the same family) in exon 3 (all three 501 C to G causing substitution Pro to Arg). The sequencing of the VHL gene was performed in nine of the 10 suspect VHL patients and in 12 of the 15 patients regarded clinically as free of VHL, and did not reveal any mutations. The missense mutations found in our series are known to be associated with pheochromocytomas<sup>25</sup>, which were present in one VHL patient and in the family of another VHL patient.

In our series, there was a female predominance (2.6:1) among 36 patients with retinal HBs for unknown reasons, in VHL (1.8:1), suspect VHL (all women) and non-VHL cases (1.5:1). Similarly, Webster et al.<sup>169</sup> found a female predominance (2.4:1) in their 17 non-VHL patients, and there was also an excess of women among the VHL (1.4:1) and non-VHL (2:1) patients, with uncertain VHL exclusion, collected from the literature by Chang et al.<sup>22</sup>. In HBs of the CNS, there is only a slight female predominance according to a literature review by Resche et al.<sup>138</sup> in concordance to our series of 110 patients (1.2:1).

#### *Definite VHL patients*

In our series, in the 11 definite VHL patients (four men, seven women), HBs of the retina were detected at a median age of 27 (range 11-65) years in concordance with the literature<sup>118</sup>. Eight VHL patients (73%) had familial disease (seven unrelated pedigrees), and three patients apparently had a new mutation. At detection, three patients (27%) had one unilateral retinal HB, six (55%) had bilateral HBs, and one had two HBs in one eye. During a median follow-up time of 12 (range 1.5-30) years, six patients developed new retinal HBs outside the already treated areas. Eventually, 21 eyes became affected, and the number of HBs varied from one to seven per eye. As other manifestations of VHL, HBs of the CNS were detected in nine of the 11 VHL patients (82%) at the median age of 32 (range 18-59) years, corresponding to the literature<sup>118</sup>, RCC in seven at the median age of 40 (range 28-57) years, somewhat later than in recent series<sup>118</sup>, and pheochromocytoma in one patient. Cysts of the internal organs were detected in nine patients (82%).

#### *Suspect VHL patients*

In general, the presence of more than one retinal HB is suggestive of VHL<sup>138,169,170</sup>. At the end of the median follow-up time of five years (range 0.2-21 years) five female patients had either bilateral HBs or more than one unilateral HB without other VHL-related neoplasms. At detection, two of the patients had bilateral HBs, one had two and one had four unilateral HBs. Two patients (one with bilateral HBs at detection) developed new lesions outside the already treated areas. The median age of 40 (range 14-45) years at primary detection, negative family history, the lack of other VHL

manifestations (one patient with a single renal cyst), and no germline mutations detected (4/5 patients studied) are findings resembling those in non-VHL patients. Only one patient has died of a non-related cause at the age of 35 years. These patients may thus have a mild form of VHL. Our detection method, i.e. direct sequencing, picks up 60-70% of VHL gene mutations, but misses large deletions<sup>25,26,161,178</sup>. These multiple HBs may also represent germline mosaicism or a segmental cell population with the VHL gene defect, or although unlikely, a local spread of the same tumor. In any case, this patient group with a favorable overall prognosis should be followed up to define the natural history of this condition. Thus, multiple HBs of the retina as well as HBs of the CNS without other VHL manifestations may represent an entity similar to schwannomatosis but without NF2<sup>50,78,102,153</sup>.

Another five female patients with a single retinal HB, detected at the median age of 37 (range 25-61) years, had visceral cysts. However, a negative family history, the lack of other VHL manifestations, and no germline mutations detected (all patients studied) suggest that the retinal HB(s) in these five patients were not related to VHL. The occurrence of visceral cysts in patients with retinal HBs (in 10% in the kidneys, and in 15% in the liver) corresponds to that of the incidental cysts in the general population<sup>18,74,95,168</sup>. Furthermore, the number of cysts per organ and per patient was less than in the definite VHL patients. Therefore, the five patients most probably represent non-VHL patients with sporadic visceral cysts.

#### *Non-VHL patients*

Fifteen of the 36 patients (nine women, six men) had only a single HB of the retina detected at the median age of 40 (range 17-58) years, later than the 28 (range 3-52) years reported in a recent series of 17 non-VHL patients<sup>169</sup>. No de novo HBs appeared during the median follow-up of two (range 0.2-17) years. The lack of other VHL manifestations, negative family history, and no germline mutations of the VHL gene (12/15 patients studied) suggest that the retinal HB was not VHL-related.

### *VHL prevalence in retinal HBs*

The prevalence of VHL in our series of 36 consecutive patients with retinal HB(s) varies between 30 and 58%, which is much higher than in our series of 110 patients with HBs of the CNS. Earlier, without the possibility of germline mutation analysis and modern imaging to exclude VHL, it was postulated that retinal HB(s) are always, or in most cases, related to VHL<sup>114,138</sup>. Recently, Webster et al.<sup>169</sup> were able to identify 17 non-VHL patients with retinal HBs collected from several ophthalmologic and genetic centers in the UK, using MR imaging and mutation analysis. Our series is the first consecutive series of patients with retinal HB(s) treated at a single center with population responsibility. Our study, which excluded VHL with meticulous multidisciplinary, should reflect the true risk of VHL, patient characteristics and outcome of vision in patients with retinal HB(s).

### *Long-term prognosis of vision in patients with retinal HB(s)*

Retinal HBs were detected at a younger age in VHL than in non-VHL patients, at least partly due to awareness of the disease in the family and earlier screening, analogous to HBs of the CNS<sup>118,138</sup> and tumors in other familial cancer syndromes<sup>52</sup>. However, Webster et al.<sup>169,170</sup> found no age difference. Retinal HBs were incidental findings in 55% of our definite VHL patients, corresponding to previous studies<sup>108</sup>, and in 40% of the non-VHL patients, less than the 63% reported by Webster et al.<sup>169</sup>. In our series, the appearance of retinal HBs did not differ between definite VHL, suspect VHL and non-VHL patients.

Six of the 11 definite VHL patients (55%) (median age of 31, range 23-65 years), two of the 10 suspect VHL patients (1/5 and 1/5, respectively) and six of the 15 non-VHL patients (40%) were asymptomatic at detection of retinal HB(s). One patient from each of the three categories had incipient HBs without draining vessels, all the others had typical mature HBs of varying sizes with dilated and tortuous draining vessels. One suspect VHL patient with visceral cysts had a single juxtapapillary HB.

Five VHL patients had visual impairment with one blind eye (median age of 27, range 11-57 years). During the follow-up, five more eyes in VHL patients lost light perception. Two VHL patients became totally blind due to retinal detachment and/or neovascular glaucoma. At detection, one eye in a suspect VHL patient had lost light perception due to vitreous hemorrhage, total retinal detachment and neovascular glaucoma

caused by a large HB. At the end of follow-up the patient was legally blind (vision <20/400 in the better eye). In two more eyes, vision remained impaired (<20/60) in spite of vitreoretinal surgery. None of the non-VHL patients, on the contrary, had visual acuity <20/60 in the affected eye.

Thus, in our series, the prognosis of vision in eyes with retinal HB(s) was more favorable in non-VHL than in definite VHL patients, whereas the outcome witnessed by Webster et al.<sup>169,170</sup> was equal in both groups. In general, the suspect VHL patients in our series had a prognosis of vision resembling that of the non-VHL patients. However, in one patient with bilateral HBs, and in another with unilateral multiple HBs, visual outcome resembled that of the definite VHL patients. No enucleations were performed in our 15 non-VHL patients, whereas two of the 17 affected non-VHL eyes were removed in the series of Webster et al.<sup>169</sup>. In our 11 definite VHL patients, all but one had bilateral disease, and at the end of the follow-up altogether six eyes (29 %) had lost light perception, one of them enucleated, and two patients were totally blind, a finding emphasizing the importance of ophthalmologic screening and early treatment of retinal HBs in VHL patients<sup>174</sup>.

#### *Early detection of VHL lesions*

The average life-expectancy of VHL patients is 40 to 50 years<sup>115</sup>. It was 50 years in our series, and all patients died due to VHL (two of RCC, and two of HBs of the CNS). Therefore, all patients with retinal HB(s) should be screened for VHL by MRI of the head and spine, upper abdominal CT or MRI; the family history should be obtained, and germline mutation analysis performed. Patients with a single retinal HB but no other VHL manifestations, negative family history and no germline mutations should remain in ophthalmologic control. Genetic counseling should be offered to all VHL patients, and annual life-long follow-up should be arranged conjointly by an ophthalmologist, a neurosurgeon, and a urologist. Retinal screening of children at risk should start as soon as co-operation permits the detection of even incipient HBs.

### **3. Gamma knife radiosurgery in 11 HBs of the CNS (III)**

#### *Response of the solid part*

In our series, CT or MRI scans were available of 10 of the 11 HBs at four to 68 (median 26) months after RS. The solid part shrunk in six HBs in a median of 30 months, while four HBs were found unchanged in a median of 14 months. The solid part of three HBs were operated on after RS. In one patient the tumor was resected at 17 months although it had reduced in size. In another patient the tumor was unchanged at 31 months, but it was removed at 51 months along with the evacuation of a de novo cyst. In one patient the tumor, unchanged at six months, was removed at 38 months because it maintained a cyst, but no imaging data was available on the size of the tumor at that time. It was not possible to determine whether RS had affected vascularity or resectability of these three HBs, and no histological specimens were available.

Single sporadic HBs rarely come to RS, because seemingly complete microsurgical removal of the solid part is almost always curative and ceases cyst formation. Chandler and Friedman<sup>21</sup> treated a non-cystic HB (10 x 15 mm) in the floor of the fourth ventricle with LINAC radiosurgery because the patient had not tolerated brain stem manipulation during open surgery. Two years after a margin dose of 15 Gy (90% isodose line, 16-mm collimator) her status was still normal and the tumor size had remained unchanged. We obtained reliable follow-up data on five sporadic cerebellar HBs. No symptoms suggesting radiation injury developed in a median follow-up time of 42 (range 21-122) months. The median tumor diameter was 14 (range 6-43) mm and the median margin dose was 15 (range 5-25) Gy. Radiological studies at a median of 19 (range 6-33) months showed that the solid part had not increased in any of the five HBs. However, the two largest tumors with diameters of 31 mm and 43 mm had been operated on at 17 and 38 months, respectively. Together these six cases indicate that RS is a well tolerated means to shrink or stabilize small and medium-sized single sporadic HBs, but the tumors so treated must be followed up for a long time. It remains to be seen how RS affects possible later resection of the solid part, the tumor vascularity and adherence to the adjacent brain.

VHL patients have an inherited tendency to develop multiple cerebellar, cerebral and spinal HBs. Microsurgery is not an ideal method to control them in the long run, because repeated exposures cause cumulative neuronal damage. Page et al.<sup>130</sup> treated

nine solid and two cystic posterior fossa HBs in four VHL patients using LINAC radiosurgery to achieve a margin dose of 30 to 35 Gy. The tumors were rather small with a median diameter of 10 (range 1.5-20) mm. Chang et al.<sup>23</sup> treated 29 HBs in 13 VHL patients using LINAC radiosurgery. The radiation dose to the tumor periphery averaged 23 (range 18-40) Gy. In our series, four solid HBs and one cystic HB in four patients were treated with a median margin dose of 25 (range 8 to 35) Gy. The median diameter of the solid part was 12 (range 10 to 24) mm. Combined follow-up imaging data of these 45 tumors suggest that RS is able to shrink or stabilize the solid part of HB associated with VHL.

#### *Response of the adjacent cyst*

The solid part of an HB has a tendency to create and maintain an adjoining cyst by a mechanism which is thus far unknown. Removal of the solid part is an adequate treatment also for the cyst, which indicates that the cyst is not maintained by an actively secreting capsule. RS is therefore targeted at the solid part of HB, and it is not feasible to irradiate the periphery of the cyst. In our series, five HBs had an associated cyst at the time of RS. Two of these five cysts required evacuation at six months, and one at 31 months after RS. Six HBs had no adjoining cyst at the time of RS, but during the follow-up one of them developed a cyst necessitating evacuation 51 months after RS. The combined follow-up data of 90 HBs in 50 patients<sup>21,23,130,131</sup>, including the present series, confirm that RS of the solid part may not prevent cyst formation. The adjoining cyst may enlarge and necessitate evacuation despite regression of the solid part, and RS of a solitary HB does not necessarily prevent formation of a de novo cyst later. The mechanism by which RS affects the endothelial cells and parenchymal cells of HB is unknown. Because the response is slow, the cyst forming secretion from HB tissue may continue for a considerable time. Consequently, removal of the solid part may become necessary if it maintains a cyst in the long run.

#### *Morbidity and tumor margin dose*

In our series, no acute adverse effects attributable to the gamma knife procedure were registered. Page et al.<sup>130</sup> used high tumor margin doses (30-35 Gy) and two of the four patients suffered transient nausea and vomiting immediately after treatment.

Overlapping fields may occur in VHL patients because of multiple HBs, and this increases the risk of delayed radiation injury. In our series, one patient had two cerebellar HBs treated in the same session, each receiving a margin dose of 25 Gy in one shot with a 14-mm collimator. At six months she developed cerebellar edema requiring a shunt and prolonged corticosteroid treatment. The patient with a suprasellar HB received a margin dose of only 8 Gy in three shots with an 18-mm collimator, but at 22 months she became confused and had severe hyponatremia due to inappropriate secretion of antidiuretic hormone (SIADH); her tumor, however, was found regressed. On the other hand, a margin dose of 20 Gy in one shot with an 8-mm collimator in an eloquent area, the midbrain, did not cause side-effects during a 13-month follow-up. In the series of Chang et al.<sup>23</sup> the radiation dose to the tumor periphery averaged 23 (range 18-40) Gy. Three out of 13 patients (23%) developed radiation necrosis during the mean follow-up of 43 months, but two of the three patients remained asymptomatic. Patrice et al.<sup>131</sup> used a lower median dose of 16 (range 12-20) Gy but three out of 22 patients required corticosteroids after RS. One patient was treated with corticosteroids eight months after RS for symptomatic mass effect prior to undergoing reoperation<sup>131</sup>. Our last five cases with a reduced dosage suggest that the solid part was controlled by a margin dose of 10-15 Gy, but as stated above, cyst formation is usually not prevented.

#### **4. IFN $\alpha$ 2a treatment in 18 HBs of the CNS and retina**

##### *Patients and HBs*

At the beginning of the IFN $\alpha$ 2a treatment, the three VHL patients had altogether 14 small untreated HBs of the CNS, two previously treated retinal HBs, and one untreated retinal HB. Two VHL patients had altogether 16 renal and two pancreatic cysts, but the third had none. The single non-VHL patient had a slowly growing HB remnant in the jugular foramen. All patients were asymptomatic in relation to these tumors. After the 12-month IFN therapy the patients were followed up for a further 9 to 10 months.

##### *Overall response*

During the 12-month IFN therapy, two of the 15 HBs of the CNS diminished slightly (13%), nine remained unchanged (60%) and four enlarged (27%). During the

subsequent nine-month follow-up, four tumors decreased slightly, six remained unchanged, and five increased slightly in diameter. These HBs were small, and some of the changes ( $\pm 1$ mm) may be due to measurement errors from the MRI scans. On the other hand, small but real changes in diameter would cause considerable volume changes. HBs of the retina were easier to monitor, being accessible to direct visual observation of appearance and size. Two of the three HBs of the retina slightly decreased during the treatment but one of them increased again after the therapy, suggesting that IFN $\alpha$ 2a diminished only their blood flow. No de novo HBs of the CNS or retina appeared during the IFN therapy, but one new lesion was detected nine months after discontinuation of the therapy. The treatment did not prevent visceral cysts from enlarging and fusing. Two VHL patients had altogether eight HBs in the spinal cord, but they did not develop marked peritumoral edema or medullary symptoms during IFN $\alpha$ 2a treatment. No unusual toxicity was observed, and the mild adverse effects observed did not necessitate the reduction of the IFN dosage or discontinuation of the treatment.

VEGF plays a role in VHL, promoting angiogenesis of HBs of the CNS and retina<sup>64</sup>. S-VEGF levels are increased in patients with disseminated cancer<sup>147</sup>, but there are no published data on the effect of IFN $\alpha$  on S-VEGF in cancer patients. In our three VHL patients, however, there was no obvious association between the S-VEGF levels, the number of HBs, and the effect of IFN therapy, but the number of patients is too small for definitive conclusions. The patients did not have polycythemia and their S-EPO levels were within normal range and remained so during the therapy. The impact of VEGF<sup>46,47</sup> in retinal pathology is thought to be mediated by the increasing mitogenic activity of endothelial cells and the permeability of the vascular wall<sup>1</sup>. Furthermore, in animal studies VEGF has associated with increased blood flow in the retina<sup>33</sup>, considered important in the pathogenesis of early diabetic retinopathy<sup>33</sup>. Thus, IFN $\alpha$ 2a may have, by counteracting VEGF, decreased blood flow in HBs as suggested by shrinkage of the two retinal HBs. Another VEGF antagonist, PKC  $\beta$  inhibitor, has been shown to decrease retinal blood flow in diabetic rats<sup>77</sup>.

#### *Dosage of IFN*

The dosage of IFN $\alpha$  in our phase II study was rather low ( $9 \times 10^6$  IU/week for 12 months). The effect on HBs could be more pronounced with a higher or denser dosage

such as  $3 \times 10^6$  IU/m<sup>2</sup>/day for up to 13 months used successfully to shrink large hemangiomas in children<sup>51</sup>. However, higher IFN doses are often poorly tolerated in long-term use, which is necessary in treating slowly growing tumors. Furthermore, there was no statistically significant correlation between dose intensity and the response rate in a review of 525 RCC patients treated with IFN $\alpha$ <sup>71</sup>. In HBs of the CNS, it is difficult to estimate the treatment effect, because the growth is slow<sup>39,124</sup> and unpredictable. In VHL patients, some tumors grow while others remain dormant. Spontaneous regression of retinal HBs has been reported<sup>172</sup>, but usually these lesions grow, and eventually cause loss of vision if left untreated<sup>174</sup>. If IFN $\alpha$ 2a treatment prevents some HBs of the CNS and retina from growing, the problem will be how to identify the potential responders. Because of the life-long tendency of VHL patients to develop HBs, IFN therapy should be long-lasting and continue for several years, possibly intermittently, to reduce adverse effects.

#### *Future trends*

More potent antiangiogenic drugs such as angiostatin and endostatin derivatives may offer means to prevent the appearance of new lesions or to shrink or stabilize established ones. These drugs may be successfully combined with radiotherapy, chemotherapy or immunotherapy.

## CONCLUSIONS

I. The frequency of VHL in 110 consecutive patients operated on for HB(s) of the CNS was 31% before the age of 25 years, 19% between 25 and 45 years, and only 2% thereafter. In the 14 VHL patients (13%), HB(s) of the CNS were detected at the median age of 33 years, followed by retinal HBs at 39 years, and RCC at 43 years. Half of the VHL patients had spinal and/or brain stem HBs at some stage in comparison to only 4-5% of non-VHL patients. Internal organ cysts in HB patients did not necessarily indicate VHL. The growth rates of non-VHL and VHL-related HBs were similar, as indicated by the median time to recurrence and the MIB-indices. The median life-span of VHL patients was 46 years, with RCC and HBs as equal causes of death.

II. About one third to one half of the 36 consecutive patients with retinal HB(s) had VHL. Internal organ cysts in patients with retinal HBs did not necessarily indicate VHL. The appearance of retinal HB(s) did not differ between VHL and non-VHL patients. The outcome of vision was less favorable in VHL patients. Women predominate (2.6:1) in patients with retinal HB(s).

III. A solitary small or medium-sized HB usually shrank or stopped growing after radiosurgery, and a margin dose of 10 to 15 Gy was sufficient. The adjoining cyst often did not respond to the radiosurgery of the solid part, but required later evacuation, even repeatedly. It is mandatory to follow-up radiosurgically treated HBs regularly by CT or preferably MRI.

IV. No de novo HBs were detected during the 12-month IFN $\alpha$ 2a therapy at a dose of  $3 \times 10^6$  IU s.c. three times per week, but one appeared nine months after discontinuation of the treatment. HBs of the CNS did not markedly decrease in size during the treatment, but the dosage used may be insufficient. IFN $\alpha$ 2a may decrease blood flow in HBs as suggested by shrinkage of two retinal HBs, but the therapy did not prevent visceral cysts from growing. The treatment was well tolerated.

## SUMMARY

Von Hippel-Lindau disease (VHL) is a rare dominantly inherited cancer syndrome predisposing to multiple hemangioblastomas (HB) of the CNS and retina, renal cell carcinomas (RCC), pancreatic carcinoma, pheochromocytomas, and visceral cysts. VHL usually reduces life to 40-50 years, with RCC and HBs of the CNS as the main causes of death. The HB is a highly vascular, benign and well-circumscribed, slowly growing solid or cystic neoplasm of the CNS and retina. In HBs of the CNS, microsurgery is the treatment of choice aided, if necessary, by preoperative embolization to reduce intraoperative bleeding. Radiosurgery offers a non-invasive means to treat HBs in eloquent brain areas. There are sporadic retinal HBs without VHL, but their prevalence has remained undefined. There is increased morbidity related to repeated microsurgery and radiosurgery of HBs of the CNS, as well as coagulation of retinal HBs. Therefore, it is justifiable to seek other approaches to treat multiple HBs. Antiangiogenic tumor therapy is targeted to small foci of migrating and proliferating endothelial cells in capillaries at sites of angiogenesis, in an attempt to inhibit tumor growth. Interferon-alpha ( $\text{IFN}\alpha$ ) is a well-tolerated drug with immunomodulatory, antiproliferative and antiangiogenic activities.

Long-term follow-up data on patients with HBs of the CNS and/or retina, treated with population responsibility and distinction of VHL, have remained scarce. The effect of radiosurgery in HBs of the CNS has remained undetermined. There are no published data on the effect of  $\text{IFN}\alpha$  therapy in HBs of the CNS and retina. The aims of this thesis were to study the VHL prevalence and long-term prognosis of 110 patients with HBs of the CNS and 36 with HBs of the retina, the results of gamma knife radiosurgery in 11 HBs of the CNS, and the impact of 12-month  $\text{IFN}\alpha 2a$  therapy in 18 HBs of the CNS and retina.

The frequency of VHL in 110 consecutive patients operated on for HB(s) of the CNS was 31% before the age of 25 years, 19% between 25 and 45 years, and only 2% thereafter. In the 14 VHL patients (13%), HB(s) of the CNS were detected at the median age of 33 years, followed by retinal HBs at 39 years, and RCC at 43 years. Half of the VHL patients had spinal and/or brain stem HBs at some stage in comparison to only 4-5% of non-VHL patients. Internal organ cysts in HB patients did not necessarily indicate VHL. The growth rates of non-VHL and VHL-related HBs were similar, as indicated by the

median time to recurrence and the MIB-indices. The median life-span of VHL patients was 46 years, with RCC and HBs as equal causes of death.

About one third to one half of the 36 consecutive patients with retinal HB(s) had VHL. Internal organ cysts in patients with retinal HBs did not necessarily indicate VHL. The appearance of retinal HB(s) did not differ between VHL and non-VHL patients. The outcome of vision was less favorable in VHL patients. Women predominate (2.6:1) in patients with retinal HB(s).

A solitary small or medium-sized HB usually shrank or stopped growing after radiosurgery, and a margin dose of 10 to 15 Gy was sufficient. The adjoining cyst often did not respond to the radiosurgery of the solid part, but required later evacuation, even repeatedly. It is mandatory to follow-up radiosurgically treated HBs regularly by CT or preferably MRI.

No de novo HBs were detected during the 12-month IFN $\alpha$ 2a therapy at a dose of  $3 \times 10^6$  IU s.c. three times per week, but one appeared nine months after discontinuation of the treatment. HBs of the CNS did not markedly decrease in size during the treatment, but the dosage used may be insufficient. IFN $\alpha$ 2a may decrease blood flow in HBs as suggested by shrinkage of two retinal HBs, but the therapy did not prevent visceral cysts from growing. The treatment was well tolerated.

## FIGURES OF VHL LESIONS

### 1. HBs of the CNS

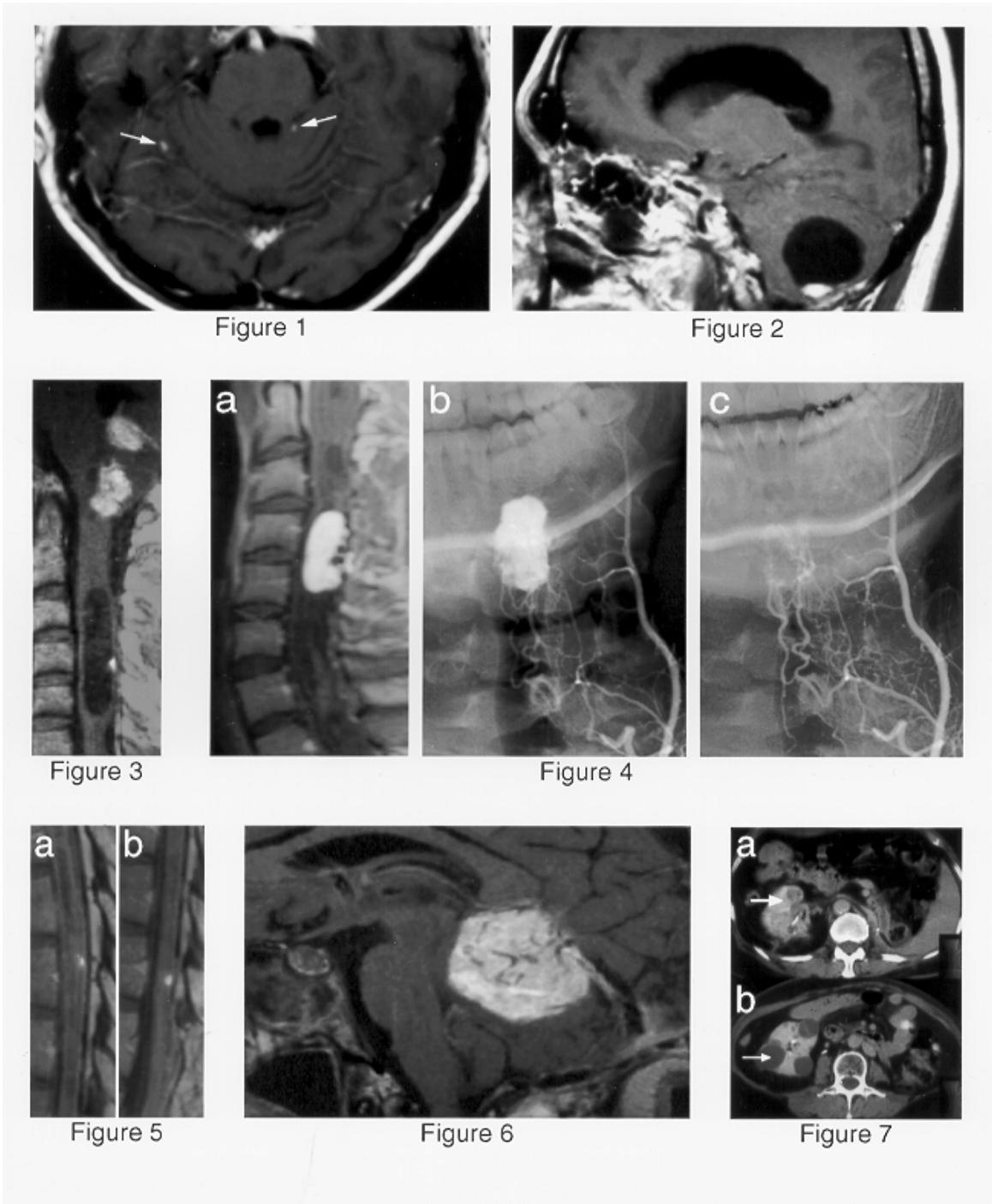


Figure 1

MRI scan of two small solid cerebellar HBs (arrows) in a 52-year-old VHL patient.

Figure 2

MRI scan of a typical cystic cerebellar HB in a 39-year-old non-VHL patient.

Figure 3

Two solid brain stem HBs and a cystic HB in the cervical spine in a 32-year-old VHL patient.

Figure 4

An HB in cervical spine in a 21-year-old VHL patient: MRI with contrast (a), superselective angiography before (b) and after (c) preoperative embolization.

Figure 5

Two small spinal HBs in the thoracic region (a and b) in the same patient as in Figure 4, three years later.

Figure 6

A large solid recurrent HB 11 years after the primary total removal in a 66-year-old non-VHL patient.

## **2. RCC and cysts**

Figure 7

Abdominal CT scan of a 64-year-old VHL patient with the right kidney removed because of RCC. The left kidney presents with RCC (a) and cysts (b).

### 3. HBs of the retina

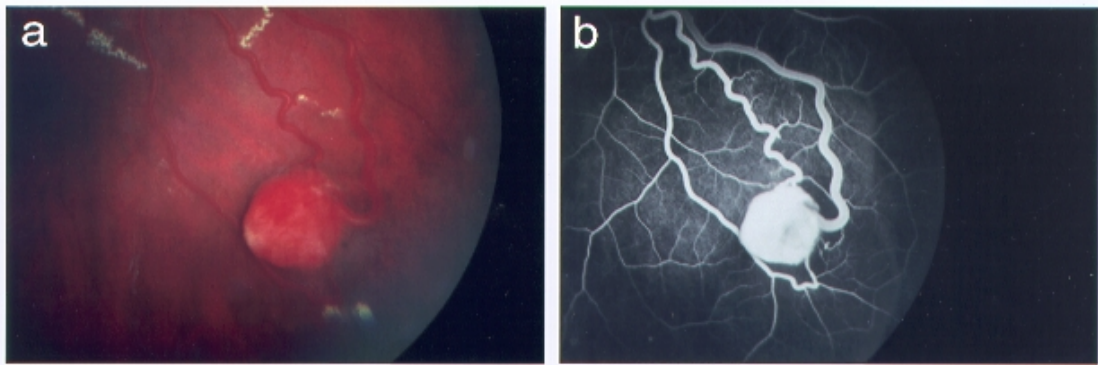


Figure 8

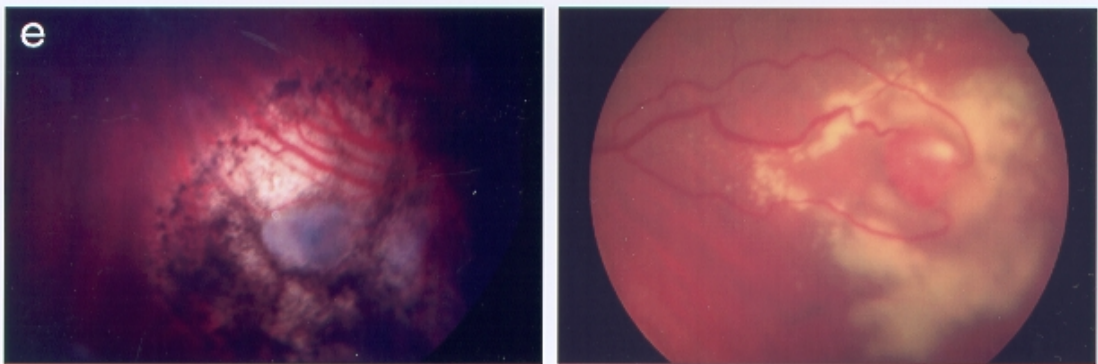
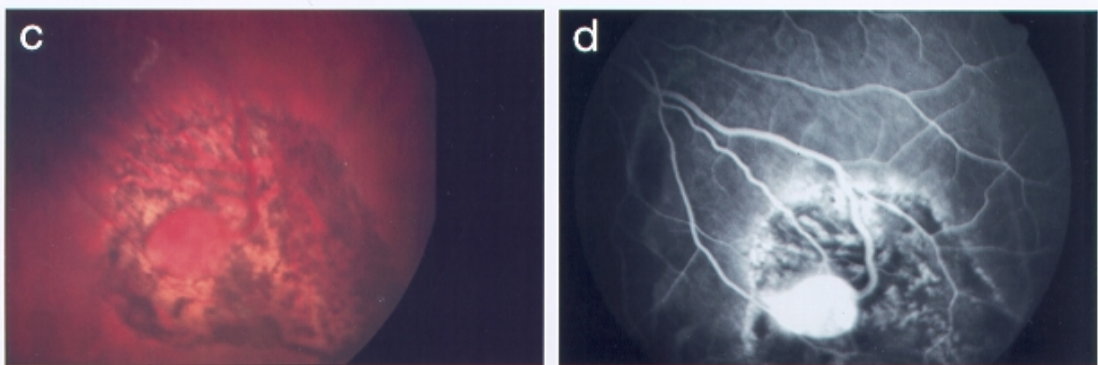


Figure 9

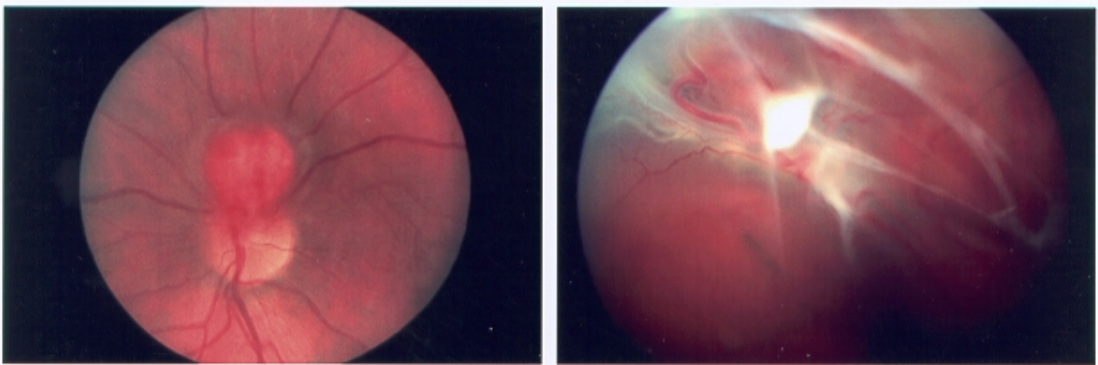


Figure 10

Figure 11

Figure 8

A typical mature HB with a draining arteriole and venule in a 40-year-old non-VHL patient: ophthalmoscopic view (a), and FA (b) before treatment; ophthalmoscopic view (c) and FA (d) at two months after cryocoagulation, showing narrowing of the feeders. Ophthalmoscopic view (e) at six months, showing shrinkage of the HB.

Figure 9

A large HB with draining vessels and lipid exudates in a 65-year-old VHL patient.

Figure 10

A juxtapapillary HB in a 25-year-old suspect VHL patient.

Figure 11

Local exudative and tractional retinal detachment caused by an HB in a 26-year-old non-VHL patient.

## ACKNOWLEDGEMENTS

Professor Juha Hernesniemi, Chief of Neurosurgery at HUCH, for his valuable comments and for providing me with excellent working conditions to finish the thesis. He is truly a giant in neurosurgery.

Professor Olli Heiskanen, former Chief of Neurosurgery at HUCH, for his comments during the early phases of the study. He offered me the possibility to enter the fascinating world of neurosurgery.

Professor Leila Laatikainen, Chief of Ophthalmology at HUCH, for her comments and kind interest.

Docent Juha Jääskeläinen for excellent supervision and friendship. Without his brilliant intellect this thesis would not have been possible.

Docent Paula Summanen for excellent supervision. I admire her profound knowledge in ophthalmology, but also her constant kindness.

Docent Tom Böhling for smooth collaboration and expert examination of the HB slides.

Docent Hannu Haapasalo for helping with the MIB-1 proliferation studies.

Docents Pauli Helén and Heikki Minn for their expert review of the thesis summary.

Professor Heikki Joensuu, Chief of Oncology at HUCH, for excellent ideas and fruitful collaboration.

Professor Juha Kere, Chief of the Finnish Genome Center, for his constructive comments and interest, and Docent Helena Kääriäinen for genetic counseling.

Sebsebe Lemeta MD for performing the laborous mutation analysis.

Young Jin Lim MDPH and Michael Söderman MD for helping with the measurement of tumor volumes in the gamma knife study.

Docent Christer Lindquist for the excellent facilities to analyze the series of HB patients treated with the gamma knife at Karolinska Hospital.

Hanna Mäenpää MDPH and Petri Salven MDPH for their expertise and fruitful collaboration.

Kristiina Poussa MD and Sirpa Rauma MD for analyzing the radiological studies.

Docents Eero Pukkala and Risto Sankila for performing the linkage analysis using the FCR database.

Markku Sainio MDPH for his extensive knowledge in molecular biology and his admirable ability to raise my spirits even during the darkest moments of the study.

Professor Antti Vaheri, Chief of the 'Ezrin-Merlin Study Group', for arranging grants allowing me time off from clinical neurosurgery to finish the thesis.

My colleagues, especially Jussi Antinheimo MDPH and Munyao Nzau MD, at the Department of Neurosurgery for fluent collaboration and support during the study.

Mr. Antti Huittinen for helping with the figures.

Mrs. Aira Lindeman for the extensive pedigree analyses and enormous help during the study.

Terttu Kaustia MA for revising the English language of the thesis summary.

Rax Rinnekangas for the outstanding cover design of the thesis summary.

My parents, sister and brother for their love and support.

Maire Taponen Foundation and HUCH Research Funds for financial support.

Helsinki, March 2000

## REFERENCES

1. Aiello LP. Vascular endothelial growth factor. 20th-century mechanisms, 21st-century therapies. *Invest Ophthalmol Vis Sci* 38:1647-1652, 1997.
2. Alexander JA, Lichtman JB, Varma VA. Ultrasound demonstration of a papillary cystadenoma of the epididymis. *J Clin Ultrasound* 19:442-445, 1991.
3. Antinheimo J, Sankila R, Carpén O, Pukkala E, Sainio M, Jääskeläinen J. Population-based analysis of sporadic and NF2-associated meningiomas and schwannomas. *Neurology* (in press) .
4. Apple DJ, Goldberg MF, Wyhinny GJ. Argon laser treatment of von Hippel-Lindau retinal angiomas. II. Histopathology of treated lesions. *Archives of Ophthalmology* 92:126-130, 1974.
5. Aprill BS, Drake AJ, 3rd, Lasseter DH, Shakir KM. Silent adrenal nodules in von Hippel-Lindau disease suggest pheochromocytoma. *Ann Intern Med* 120:485-487, 1994.
6. Atuk NO, Stolle C, Owen JA, Jr., Carpenter JT, Vance ML. Pheochromocytoma in von Hippel-Lindau disease: clinical presentation and mutation analysis in a large, multigenerational kindred. *J Clin Endocrinol Metab* 83:117-120, 1998.
7. Augsburger JJ, Shields JA, Goldberg RE. Classification and management of hereditary retinal angiomas. *Int Ophthalmol* 4:93-106, 1981.
8. Balcer LJ, Galetta SL, Curtis M, Maguire A, Judy K. von Hippel-Lindau disease manifesting as a chiasmal syndrome. *Surv Ophthalmol* 39:302-306, 1995.
9. Beerman MH, Fromkes JJ, Carey LC, Thomas FB. Pancreatic cystadenoma in von Hippel-Lindau disease: an unusual cause of pancreatic and common bile duct obstruction. *J Clin Gastroenterol* 4:537-540, 1982.
10. Benson M, Mody C, Rennie I, Talbot J. Haemangioma of the optic disc. *Graefes Arch Clin Exp Ophthalmol* 228:332-334, 1990.
11. Beroud C, Joly D, Gallou C, Staroz F, Orfanelli MT, Junien C. Software and database for the analysis of mutations in the VHL gene. *Nucleic Acids Res* 26:256-258, 1998.
12. Boughey AM, Fletcher NA, Harding AE. Central nervous system haemangioblastoma: a clinical and genetic study of 52 cases. *J Neurol Neurosurg Psychiatry* 53:644-648, 1990.

13. Brodkey JA, Buchignani JA, O'Brien TF. Hemangioblastoma of the radial nerve: case report. *Neurosurgery* 36:198-200; discussion 200-191, 1995.
14. Brown DF, Gazdar AF, White CL, 3rd, Yashima K, Shay JW, Rushing EJ. Human telomerase RNA expression and MIB-1 (Ki-67) proliferation index distinguish hemangioblastomas from metastatic renal cell carcinomas. *J Neuropathol Exp Neurol* 56:1349-1355, 1997.
15. Browne G, Jefferson JA, Wright GD, Hughes AE, Doherty CC, Nevin NC, Keogh JA. Von Hippel-Lindau disease: an important differential diagnosis of polycystic kidney disease. *Nephrol Dial Transplant* 12:1132-1136, 1997.
16. Böhling T, Haltia M, Rosenlöf K, Fyhrquist F. Erythropoietin in capillary hemangioblastoma. An immunohistochemical study. *Acta Neuropathol* 74:324-328, 1987.
17. Böhling T, Hatva E, Plate K, Haltia M, Alitalo K. von Hippel-Lindau disease and capillary hemangioblastoma. In: Kleihues P, Cavenee WK, editors. *Pathology & Genetics Tumours of the Nervous System*. International Agency for Research on Cancer. Lyon, 1997, 179-181.
18. Caremani M, Vincenti A, Benci A, Sassoli S, Tacconi D. Echographic epidemiology of non-parasitic hepatic cysts. *J Clin Ultrasound* 21:115-118, 1996.
19. Carpiello B, Orru MG, Baita A, Pariante CM, Farci G. Mania induced by withdrawal of treatment with interferon alfa. *Arch Gen Psychiatry* 55:88-89, 1998.
20. Carson JJ, Gold LH, Barton AB, Biss RT. Fatality and interferon alpha for malignant melanoma. *Lancet* 352:1443-1444, 1998.
21. Chandler HC, Jr., Friedman WA. Radiosurgical treatment of a hemangioblastoma: case report. *Neurosurgery* 34:353-355; discussion 355, 1994.
22. Chang JH, Spraul CW, Lynn ML, Drack A, Grossniklaus HE. The two-stage mutation model in retinal hemangioblastoma. *Ophthalmic Genet* 19:123-130, 1998.
23. Chang SD, Meisel JA, Hancock SL, Martin DP, McManus M, Adler JR. Treatment of hemangioblastomas in von Hippel-Lindau disease with linear accelerator-based radiosurgery. *Neurosurgery* 43:28-34; discussion 34-25, 1998.
24. Chazono M, Shiba R, Funasaki H, Soshi S, Hattori A, Fujii K. Hemangioblastoma of the L-5 nerve root - Case illustration. *Journal of Neurosurgery* 90:160, 1999.

25. Chen F, Kishida T, Yao M, Hustad T, Glavac D, Dean M, Gnarr JR, Orcutt ML, Duh FM, Glenn G, et al. Germline mutations in the von Hippel-Lindau disease tumor suppressor gene: correlations with phenotype. *Hum Mutat* 5:66-75, 1995.
26. Chen F, Slife L, Kishida T, Mulvihill J, Tisherman SE, Zbar B. Genotype-phenotype correlation in von Hippel-Lindau disease: identification of a mutation associated with VHL type 2A. *J Med Genet* 33:716-717, 1996.
27. Chew SL. Pheochromocytoma and familial tumour syndromes. *Clin Endocrinol (Oxf)* 40:715-716, 1994.
28. Chew SL, Dacie JE, Reznek RH, Newbould EC, Sheaves R, Trainer PJ, Lowe DG, Shand WS, Hungerford J, Besser GM, et al. Bilateral pheochromocytomas in von Hippel-Lindau disease: diagnosis by adrenal vein sampling and catecholamine assay. *Q J Med* 87:49-54, 1994.
29. Choyke PL. Inherited cystic diseases of the kidney. *Radiologic Clinics of North America* 34:925-946, 1996.
30. Choyke PL, Glenn GM, Wagner JP, Lubensky IA, Thakore K, Zbar B, Linehan WM, Walther MM. Epididymal cystadenomas in von Hippel-Lindau disease. *Urology* 49:926-931, 1997.
31. Choyke PL, Glenn GM, Walther MM, Patronas NJ, Linehan WM, Zbar B. von Hippel-Lindau disease: genetic, clinical, and imaging features. *Radiology* 194:629-642, 1995.
32. Choyke PL, Glenn GM, Walther MM, Zbar B, Weiss GH, Alexander RB, Hayes WS, Long JP, Thakore KN, Linehan WM. The natural history of renal lesions in von Hippel-Lindau disease: a serial CT study in 28 patients. *Am J Roentgenol* 159:1229-1234, 1992.
33. Clermont AC, Aiello LP, Mori F, Aiello LM, Bursell SE. Vascular endothelial growth factor and severity of nonproliferative diabetic retinopathy mediate retinal hemodynamics in vivo: a potential role for vascular endothelial growth factor in the progression of nonproliferative diabetic retinopathy. *Am J Ophthalmol* 124:433-446, 1997.
34. Coffey RJ, Cascino TL, Shaw EG. Radiosurgical treatment of recurrent hemangiopericytomas of the meninges: preliminary results. *J Neurosurg* 78:903-908, 1993.
35. Cohen MC, Huberman MS, Nesto RW. Recombinant alpha 2 interferon-related cardiomyopathy. *Am J Med* 85:549-551, 1988.

36. Cristante L, Herrmann HD. Surgical management of intramedullary hemangioblastoma of the spinal cord. *Acta Neurochir (Wien)* 141:333-339, 1999.
37. Crossey PA, Richards FM, Foster K, Green JS, Prowse A, Latif F, Lerman MI, Zbar B, Affara NA, Ferguson-Smith MA, et al. Identification of intragenic mutations in the von Hippel-Lindau disease tumour suppressor gene and correlation with disease phenotype. *Hum Mol Genet* 3:1303-1308, 1994.
38. D'Amico DJ. Diseases of the retina. *N Engl J Med* 331:95-106, 1994.
39. de la Monte SM, Horowitz SA. Hemangioblastomas: clinical and histopathological factors correlated with recurrence. *Neurosurgery* 25:695-698, 1989.
40. de Souza Andrade J, Bambirra EA, Bicalho OJ, de Souza AF. Bilateral papillary cystadenoma of the epididymis as a component of von Hippel-Lindau's syndrome: report of a case presenting as infertility. *J Urol* 133:288-289, 1985.
41. Decker HJ, Weidt EJ, Brieger J. The von Hippel-Lindau tumor suppressor gene. A rare and intriguing disease opening new insight into basic mechanisms of carcinogenesis. *Cancer Genet Cytogenet* 93:74-83, 1997.
42. Dippel E, Zouboulis CC, Tebbe B, Orfanos CE. Myopathic syndrome associated with long-term recombinant interferon alfa treatment in 4 patients with skin disorders. *Arch Dermatol* 134:880-881, 1998.
43. Dowling J, editor. *The retina: an approachable part of the brain*. Belknap Press of Harvard University Press. Cambridge, MA, 1987.
44. Duan DR, Humphrey JS, Chen DY, Weng Y, Sukegawa J, Lee S, Gnarr JR, Linehan WM, Klausner RD. Characterization of the VHL tumor suppressor gene product: localization, complex formation, and the effect of natural inactivating mutations. *Proc Natl Acad Sci U S A* 92:6459-6463, 1995.
45. Duan DR, Pause A, Burgess WH, Aso T, Chen DY, Garrett KP, Conaway RC, Conaway JW, Linehan WM, Klausner RD. Inhibition of transcription elongation by the VHL tumor suppressor protein. *Science* 269:1402-1406, 1995.
46. Dvorak HF, Brown LF, Detmar M, Dvorak AM. Vascular permeability factor/vascular endothelial growth factor, microvascular hyperpermeability, and angiogenesis. *Am J Pathol* 146:1029-1039, 1995.
47. Dvorak HF, Gresser I. Microvascular injury in pathogenesis of interferon-induced necrosis of subcutaneous tumors in mice. *J Natl Cancer Inst* 81:497-502, 1989.

48. Ercan M, Kahraman S, Basgul E, Aypar U. Anaesthetic management of a patient with von Hippel-Lindau disease: a combination of bilateral pheochromocytoma and spinal cord haemangioblastoma. *Eur J Anaesthesiol* 13:81-83, 1996.
49. Eskridge JM, McAuliffe W, Harris B, Kim DK, Scott J, Winn HR. Preoperative endovascular embolization of craniospinal hemangioblastomas. *AJNR Am J Neuroradiol* 17:525-531, 1996.
50. Evans D, Mason S, Huson S, Ponder M, Harding A, Strachan T. Spinal and cutaneous schwannomatosis is a variant form of type 2 neurofibromatosis: a clinical and molecular study. *J Neurol Neurosurg Psychiatry* 62:361-366, 1997.
51. Ezekowitz RA, Mulliken JB, Folkman J. Interferon alfa-2a therapy for life-threatening hemangiomas of infancy. *N Engl J Med* 326:1456-1463, 1992.
52. Fearon ER. Human cancer syndromes: clues to the origin and nature of cancer. *Science* 278:1043-1050, 1997.
53. Filling-Katz MR, Choyke PL, Oldfield E, Charnas L, Patronas NJ, Glenn GM, Gorin MB, Morgan JK, Linehan WM, Seizinger BR, et al. Central nervous system involvement in von Hippel-Lindau disease. *Neurology* 41:41-46, 1991.
54. Fishman RS, Bartholomew LG. Severe pancreatic involvement in three generations in von Hippel-Lindau disease. *Mayo Clin Proc* 54:329-331, 1979.
55. Flamme I, Krieg M, Plate KH. Up-regulation of vascular endothelial growth factor in stromal cells of hemangioblastomas is correlated with up-regulation of the transcription factor HRF/HIF-2 alpha. *Am J Pathol* 153:25-29, 1998.
56. Folkman J. Angiogenesis in cancer, vascular, rheumatoid and other disease. *Nat Med* 1:27-31, 1995.
57. Folkman J. Clinical applications of research on angiogenesis. *Seminars in Medicine of the Beth Israel Hospital, Boston. N Engl J Med* 333:1757-1763, 1995.
58. Frassoldati A, Lamparelli T, Federico M, Annino L, Capnist G, Pagnucco G, Dini E, Resegotti L, Damasio EE, Silingardi V. Hairy cell leukemia: a clinical review based on 725 cases of the Italian Cooperative Group (ICGHCL). *Italian Cooperative Group for Hairy Cell Leukemia. Leuk Lymphoma* 13:307-316, 1994.
59. Friedman WA, Bova FJ, Mendenhall WM. Linear accelerator radiosurgery for arteriovenous malformations: the relationship of size to outcome. *J Neurosurg* 82:180-189, 1995.

60. Giannini C, Scheithauer BW, Hellbusch LC, Rasmussen AG, Fox MW, McCormick SR, Davis DH. Peripheral nerve hemangioblastoma. *Mod Pathol* 11:999-1004, 1998.
61. Gläsker S, Bender BU, Apel TW, Natt E, van Velthoven V, Scheremet R, Zentner J, Neumann HPH. The impact of molecular genetic analysis of the VHL gene in patients with haemangioblastomas of the central nervous system. *J Neurol Neurosurg Psychiatry* 67:758-762, 1999.
62. Gnarr JR, Glenn GM, Latif F, Anglard P, Lerman MI, Zbar B, Linehan WM. Molecular genetic studies of sporadic and familial renal cell carcinoma. *Urol Clin North Am* 20:207-216, 1993.
63. Gnarr JR, Tory K, Weng Y, Schmidt L, Wei MH, Li H, Latif F, Liu S, Chen F, Duh FM, et al. Mutations of the VHL tumour suppressor gene in renal carcinoma. *Nat Genet* 7:85-90, 1994.
64. Gnarr JR, Zhou S, Merrill MJ, Wagner JR, Krumm A, Papavassiliou E, Oldfield EH, Klausner RD, Linehan WM. Post-transcriptional regulation of vascular endothelial growth factor mRNA by the product of the VHL tumor suppressor gene. *Proc Natl Acad Sci U S A* 93:10589-10594, 1996.
65. Goldfarb DA. Nephron-sparing surgery and renal transplantation in patients with renal cell carcinoma and von Hippel-Lindau disease. *J Intern Med* 243:563-567, 1998.
66. Goldfarb DA, Neumann HP, Penn I, Novick AC. Results of renal transplantation in patients with renal cell carcinoma and von Hippel-Lindau disease. *Transplantation* 64:1726-1729, 1997.
67. Goldsmith DJA, Thomas P. von Hippel-Lindau disease. *N Engl J Med* 340:1880, 1999.
68. Grossniklaus HE, Thomas JW, Vignesvaran N, Jarrett WHd. Retinal hemangioblastoma. A histologic, immunohistochemical, and ultrastructural evaluation. *Ophthalmologie* 99:140-145, 1992.
69. Haapasalo H, Isola J, Sallinen P, Kalimo H, Helin H, Rantala I. Aberrant p53 expression in astrocytic neoplasms of the brain: association with proliferation. *Am J Pathol* 142:1347-1351, 1993.
70. Hatva E, Böhling T, Jääskeläinen J, Persico MG, Haltia M, Alitalo K. Vascular growth factors and receptors in capillary hemangioblastomas and hemangiopericytomas. *Am J Pathol* 148:763-775, 1996.

71. Hernberg M, Pyrhönen S, Muhonen T. Regimens with or without interferon-alpha as treatment for metastatic melanoma and renal cell carcinoma: an overview of randomized trials. *J Immunother* 22:145-154, 1999.
72. Hes FJ, Slootweg PJ, van Vroonhoven T, Hene RJ, Feldberg MAM, Zewald RA, van Amstel JKP, Hoppener JWM, Pearson PL, Lips CJM. Management of renal cell carcinoma in von Hippel-Lindau disease. *Eur J Clin Invest* 29:68-75, 1999.
73. Horton JC, 4th. HGR, Fisher JW, Hoyt WF. von Hippel-Lindau disease and erythrocytosis: radioimmunoassay of erythropoietin in cyst fluid from a brainstem hemangioblastoma. *Neurology* 41:753-754, 1991.
74. Howard JM. Cystic neoplasms and true cysts of the pancreas. *Surg Clin North Am* 69:651-665, 1989.
75. Iliopoulos O, Kibel A, Gray S, Kaelin WG, Jr. Tumour suppression by the human von Hippel-Lindau gene product. *Nat Med* 1:822-826, 1995.
76. Imes RK, Monteiro ML, Hoyt WF. Incipient hemangioblastoma of the optic disk. *Am J Ophthalmol* 98:116, 1984.
77. Ishii H, Jirousek MR, Koya D, Takagi C, Xia P, Clermont A, Bursell SE, Kern TS, Ballas LM, Heath WF, Stramm LE, Feener EP, King GL. Amelioration of vascular dysfunctions in diabetic rats by an oral PKC beta inhibitor. *Science* 272:728-731, 1996.
78. Jacoby LB, Jones D, Davis K, Kronn D, Short MP, Gusella J, MacCollin M. Molecular analysis of the NF2 tumor-suppressor gene in schwannomatosis. *Am J Hum Genet* 61:1293-1302, 1997.
79. Julow J, Balint K, Gortvai P, Pasztor E. Posterior fossa haemangioblastomas. *Acta Neurochir (Wien)* 128:109-114, 1994.
80. Kaelin WG, Iliopoulos O, Lonergan KM, Ohh M. Functions of the von Hippel-Lindau tumour suppressor protein. *J Intern Med* 243:535-539, 1998.
81. Kanno H, Kondo K, Ito S, Yamamoto I, Fujii S, Torigoe S, Sakai N, Hosaka M, Shuin T, Yao M. Somatic mutations of the von Hippel-Lindau tumor suppressor gene in sporadic central nervous system hemangioblastomas. *Cancer Res* 54:4845-4847, 1994.
82. Kempermann G, Neumann HP, Scheremet R, Volk B, Mann W, Gilsbach J, Laszig R. Deafness due to bilateral endolymphatic sac tumours in a case of von Hippel-Lindau syndrome. *J Neurol Neurosurg Psychiatry* 61:318-320, 1996.
83. Kerr DJ, Scheithauer BW, Miller GM, Ebersold MJ, McPhee TJ. Hemangioblastoma of the optic nerve: case report. *Neurosurgery* 36:573-580; discussion 580-571, 1995.

84. Kibel A, Iliopoulos O, DeCaprio JA, Kaelin WG, Jr. Binding of the von Hippel-Lindau tumor suppressor protein to Elongin B and C. *Science* 269:1444-1446, 1995.
85. Kirkwood JM, Strawderman MH, Ernsthoff MS, Smith TJ, Borden EC, Blum RH. Interferon alfa-2b adjuvant therapy of high risk resected cutaneous melanoma: the Eastern Cooperative Oncology Group Trial EST 1684. *J Clin Oncol* 14:7-17, 1996.
86. Kirsch M, Strasser J, Allende R, Bello L, Zhang J, Black PM. Angiostatin suppresses malignant glioma growth in vivo. *Cancer Res* 58:4654-4659, 1998.
87. Kleihues P, Burger PC. *Histological Types of Tumours of the Central Nervous System*, ed 2. Springer-Verlag :41-42, 1993.
88. Kondziolka D, Lunsford LD, Flickinger JC, Kestle JR. Reduction of hemorrhage risk after stereotactic radiosurgery for cavernous malformations. *J Neurosurg* 83:825-831, 1995.
89. Kreusel KM, Bornfeld N, Lommatzsch A, Wessing A, Foerster MH. Ruthenium-106 brachytherapy for peripheral retinal capillary hemangioma. *Ophthalmology* 105:1386-1392, 1998.
90. Kuiper RA, Schellens JH, Blijham GH, Beijnen JH, Voest EE. Clinical research on antiangiogenic therapy. *Pharmacol Res* 37:1-16, 1998.
91. Laatikainen L, Immonen I, Summanen P. Peripheral retinal angiomalike lesion and macular pucker. *Am J Ophthalmol* 108:563-566, 1989.
92. Lamiell JM, Salazar FG, Hsia YE. von Hippel-Lindau disease affecting 43 members of single kindred. *Medicine* 68:1-29, 1989.
93. Latif F, Duh FM, Gnarr J, Tory K, Kuzmin I, Yao M, Stackhouse T, Modi W, Geil L, Schmidt L, et al. von Hippel-Lindau syndrome: cloning and identification of the plasma membrane Ca<sup>++</sup>-transporting ATPase isoform 2 gene that resides in the von Hippel-Lindau gene region. *Cancer Res* 53:861-867, 1993.
94. Latif F, Tory K, Gnarr J, Yao M, Duh FM, Orcutt ML, Stackhouse T, Kuzmin I, Modi W, Geil L, et al. Identification of the von Hippel-Lindau disease tumor suppressor gene. *Science* 260:1317-1320, 1993.
95. Laucks SP, Jr., McLachlan MS. Aging and simple cysts of the kidney. *Br J Radiol* 54:12-14, 1981.
96. Lee SR, Sanches J, Mark AS, Dillon WP, Norman D, Newton TH. Posterior fossa hemangioblastomas: MR imaging. *Radiology* 171:463-468, 1989.
97. Lindau A. Studien über Kleinhirncysten. *APMIS Suppl* :1-128 Suppl I, 1926.

98. Lindau A. Zur Frage der Angiomatosis Retinae und ihrer Hirnkomplikationen. *Acta Ophthalmol Scand* 4:193-226, 1927.
99. Lindquist C, Guo WY, Karlsson B, Steiner L. Radiosurgery for venous angiomas. *J Neurosurg* 78:531-536, 1993.
100. Lips CJM. Clinical management of the multiple endocrine neoplasia syndromes: results of a computerized opinion poll at the sixth international workshop on multiple endocrine neoplasia and von Hippel-Lindau disease. *J Intern Med* 243:589-594, 1998.
101. Lunsford LD, Kondziolka D, Flickinger JC, Bissonette DJ, Jungreis CA, Maitz AH, Horton JA, Coffey RJ. Stereotactic radiosurgery for arteriovenous malformations of the brain. *J Neurosurg* 75:512-524, 1991.
102. MacCollin M, Woodfin W, Kronn D, Short MP. Schwannomatosis: a clinical and pathologic study. *Neurology* 46:1072-1079, 1996.
103. Macheimer R, Williams JM, Sr. Pathogenesis and therapy of traction detachment in various retinal vascular diseases. *Am J Ophthalmol* 105:170-181, 1988.
104. Maher ER, Iselius L, Yates JR, Littler M, Benjamin C, Harris R, Sampson J, Williams A, Ferguson-Smith MA, Morton N. von Hippel-Lindau disease: a genetic study. *J Med Genet* 28:443-447, 1991.
105. Maher ER, Kaelin WG, Jr. von Hippel-Lindau disease. *Medicine* 76:381-391, 1997.
106. Maher ER, Webster AR, Richards FM, Green JS, Crossey PA, Payne SJ, Moore AT. Phenotypic expression in von Hippel-Lindau disease: correlations with germline VHL gene mutations. *J Med Genet* 33:328-332, 1996.
107. Maher ER, Yates JR, Ferguson-Smith MA. Statistical analysis of the two stage mutation model in von Hippel-Lindau disease, and in sporadic cerebellar hemangioblastoma and renal cell carcinoma. *J Med Genet* 27:5, 1990.
108. Maher ER, Yates JR, Harries R, Benjamin C, T. HRMA, Ferguson-Smith MA. Clinical features and natural history of von Hippel-Lindau disease. *Q J Med* 77:1151-1163, 1990.
109. Manski TJ, Heffner DK, Glenn GM, Patronas NJ, Pikus AT, Katz D, Lebovics R, Sledjeski K, Choyke PL, Zbar B, Linehan WM, Oldfield EH. Endolymphatic sac tumors. A source of morbid hearing loss in von Hippel-Lindau disease. *JAMA* 277:1461-1466, 1997.
110. McDonald HR, Schatz H, Johnson RN, Abrams GW, Brown GC, Brucker AJ, Han DP, Lewis H, Mieler WF, Meyers S. Vitrectomy in eyes with peripheral retinal angioma

associated with traction macular detachment. *Ophthalmology* 103:329-335 discussion 334-325, 1996.

111. Melmon K, Rosen S. Lindau's disease. Review of the literature and study of a large kindred. *Am J Med* 36:595-617, 1964.

112. Miller AB, Hoogstraten B, Staquet M, Winkler A. Reporting results of cancer treatment. *Cancer* 47:207-214, 1981.

113. Munt B, Erb S, Humphries K, Shepherd J, Scudamore C, Anderson F, Lam V, Shackleton C, Krystal G. Monitoring hemangioblastoma tumor burden using plasma erythropoietin levels. *Int J Hematol* 56:185-187, 1992.

114. Neumann HP. Basic criteria for clinical diagnosis and genetic counselling in von Hippel-Lindau syndrome. *Vasa* 16:220-226, 1987.

115. Neumann HP. Prognosis of von Hippel-Lindau syndrome. *Vasa* 16:309-311, 1987.

116. Neumann HP, Berger DP, Sigmund G, Blum U, Schmidt D, Parmer RJ, Volk B, Kirste G. Pheochromocytomas, multiple endocrine neoplasia type 2, and von Hippel-Lindau disease. *N Engl J Med* 329:1531-1538, 1993.

117. Neumann HP, Eggert HR, K. W, Friedburg H, Wiestler OD, Schollmeyer P. Hemangioblastomas of the central nervous system. A 10-year study with special reference to von Hippel-Lindau syndrome. *J Neurosurg* 70:24-30, 1989.

118. Neumann HP, Lips CJ, Hsia YE, Zbar B. von Hippel-Lindau syndrome. *Brain Pathol* 5:181-193, 1995.

119. Neumann HP, Schollmeyer P, Eggert HR, Jelkmann W, Wiestler OD. Serum erythropoietin levels in von Hippel-Lindau syndrome. *J Neurol Neurosurg Psychiatry* 54:746-747, 1991.

120. Neumann HP, Zbar B. Renal cysts, renal cancer and von Hippel-Lindau disease. *Kidney Int* 51:16-26, 1997.

121. Neumann HPH, Bender BU, Berger DP, Laubenberger J, Schultze-Seemann W, Wetterauer U, Ferstl FJ, Herbst EW, Schwarzkopf G, Hes FJ, Lips CJM, Lamiell JM, Masek O, Riegler P, Mueller B, Glavac D, Brauch H. Prevalence, morphology and biology of renal cell carcinoma in von Hippel-Lindau disease compared to sporadic renal cell carcinoma. *J Urol* 160:1248-1254, 1998.

122. Neumann HPH, Bender BU, Reincke M, Eggstein S, Laubenberger J, Kirste G. Adrenal-sparing surgery for pheochromocytoma. *Br J Surg* 86:94-97, 1999.

123. Nicholson D, editor. Capillary haemangioma of the retina and von Hippel-Lindau disease, in Ogden T, Schachat A, eds. *Retina*. Vol 1. Mosby. St. Louis, 1994: 633-640.
124. Niemelä M, Lemeta S, Summanen P, et al. Long-term prognosis of haemangioblastoma of the CNS: impact of von Hippel-Lindau disease. *Acta Neurochir (Wien)* 141:1147-1156, 1999.
125. Niemelä M, Lim YJ, Söderman M, Jääskeläinen J, Lindquist C. Gamma knife radiosurgery in 11 hemangioblastomas. *J Neurosurg* 85:591-596, 1996.
126. Ohh M, Kaelin WG. The von Hippel-Lindau tumour suppressor protein: new perspectives. *Mol Med Today* 5:257-263, 1999.
127. O'Reilly MS. Angiostatin: an endogenous inhibitor of angiogenesis and of tumor growth. *EXS* 79:273-294, 1997.
128. O'Reilly MS, Boehm T, Shing Y, Fukai N, Vasios G, Lane WS, Flynn E, Birkhead JR, Olsen BR, Folkman J. Endostatin: an endogenous inhibitor of angiogenesis and tumor growth. *Cell* 88:277-285, 1997.
129. Pack SD, Zbar B, Pak E, Ault DO, Humphrey JS, Pham T, Hurley K, Weil RJ, Park WS, Kuzmin I, Stolle C, Glenn G, Liotta LA, Lerman MI, Klausner RD, Linehan WM, Zhuang ZP. Constitutional von Hippel-Lindau (VHL) gene deletions detected in VHL families by fluorescence in situ hybridization. *Cancer Res* 59:5560-5564, 1999.
130. Page KA, Wayson K, Steinberg GK, Adler JR, Jr. Stereotaxic radiosurgical ablation: an alternative treatment for recurrent and multifocal hemangioblastomas. A report of four cases. *Surg Neurol* 40:424-428, 1993.
131. Patrice SJ, Sneed PK, Flickinger JC, Shrieve DC, Pollock BE, Alexander E, 3rd, Larson DA, Kondziolka DS, Gutin PH, Wara WM, McDermott MW, Lunsford LD, Loeffler JS. Radiosurgery for hemangioblastoma: results of a multiinstitutional experience. *Int J Radiat Oncol Biol Phys* 35:493-499, 1996.
132. Penn I. The effect of immunosuppression on pre-existing cancers. *Transplantation* 55:742-747, 1993.
133. Plate KH, Breier G, Weich HA, Risau W. Vascular endothelial growth factor is a potential tumour angiogenesis factor in human gliomas in vivo. *Nature* 359:845-848, 1992.
134. Pyrhönen S, Salminen E, Ruutu M, Lehtonen T, Nurmi M, Tammela T, Juusela H, Rintala E, Hietanen P, Kellokumpu-Lehtinen PL. Prospective randomized trial of

interferon alfa-2a plus vinblastine versus vinblastine alone in patients with advanced renal cell cancer. *J Clin Oncol* 17:2859-2867, 1999.

135. Reichard EAP, Roubidoux MA, Dunnick NR. Renal neoplasms in patients with renal cystic diseases. *Abdom Imaging* 23:237-248, 1998.

136. Reinhold U, Hartl C, Hering R, Hoeft A, Kreysel HW. Fatal rhabdomyolysis and multiple organ failure associated with adjuvant high-dose interferon alfa in malignant melanoma. *Lancet* 349:540-541, 1997.

137. Rengachary SS, Suskid DL. Hemangioblastomas. In: Apuzzo MLJ, editor. *Brain Surgery. Complication Avoidance and Management*. Churchill Livingstone. New York, 1993, 1825-1833.

138. Resche F, Moisan JP, Mantoura J, de Kersaint-Gilly A, Andre MJ, Perrin-Resche I, Menegalli-Boggelli D, Lajat Y, Richard S. Haemangioblastoma, haemangioblastomatosis, and von Hippel-Lindau disease. *Adv Tech Stand Neurosurg* 20:197-304, 1993.

139. Richard S, Beigelmann C, Gerber S, van Effenterre R, Gaudric A, Sahel M, Binaghi M, de Kersaint-Gilly A, Houtteville J, Brunon JP. L'hemangioblastome existe-t-il en dehors de la maladie de von Hippel-Lindau? *Neurochirurgie* 40:145-154, 1994.

140. Richard S, Campello C, Taillandier L, Parker F, Resche F. Haemangioblastoma of the central nervous system in von Hippel-Lindau disease. *Journal of Internal Medicine* 243:547-553, 1998.

141. Richards FM, Maher ER, Latif F, Phipps ME, Tory K, Lush M, Crossey PA, Oostra B, Enblad P, Gustavson KH, et al. Detailed genetic mapping of the von Hippel-Lindau disease tumour suppressor gene. *J Med Genet* 30:104-107, 1993.

142. Richards FM, Payne SJ, Zbar B, Affara NA, Ferguson-Smith MA, Maher ER. Molecular analysis of de novo germline mutations in the von Hippel-Lindau disease gene. *Hum Mol Genet* 4:2139-2143, 1995.

143. Risau W. Mechanisms of angiogenesis. *Nature* 386:671-674, 1997.

144. Roach ES. von Hippel-Lindau disease - How does one gene cause multiple tumors? *Neurology* 53:7-8, 1999.

145. Rubio A, Meyers SP, Powers JM, Nelson CN, de Papp EW. Hemangioblastoma of the optic nerve. *Hum Pathol* 25:1249-1251, 1994.

146. Sallinen P, Haapasalo H, Kerttula T, Rantala I, Kalimo H, Collan Y, Isola J, Helin H. Sources of variation in the assessment of cell proliferation using proliferating cell nuclear antigen immunohistochemistry. *Anal Quant Cytol Histol* 16:261-268, 1994.
147. Salven P, Mäenpää H, Orpana A, Alitalo K, Joensuu H. Serum vascular endothelial growth factor is often elevated in disseminated cancer. *Clinical Cancer Research* 3:647-651, 1997.
148. Salven P, Teerenhovi L, Joensuu H. A high pretreatment serum vascular endothelial growth factor concentration is associated with poor outcome in non-Hodgkin's lymphoma. *Blood* 90:3167-3172, 1997.
149. Samii M, Klekamp J. Surgical results of 100 intramedullary tumors in relation to accompanying syringomyelia. *Neurosurgery* 35:865-873; discussion 873, 1994.
150. Sawin PD, Follett KA, Wen BC, Laws ER, Jr. Symptomatic intrasellar hemangioblastoma in a child treated with subtotal resection and adjuvant radiosurgery. Case report. *Journal of Neurosurgery* 84:1046-1050, 1996.
151. Schmidt D, Neumann HP. Retinal vascular hamartoma in von Hippel-Lindau disease. *Archives of Ophthalmology* 113:1163-1167, 1995.
152. Seppälä MT, Haltia MJ, Sankila RJ, Jääskeläinen JE, Heiskanen O. Long-term outcome after removal of spinal schwannoma: a clinicopathological study of 187 cases. *Journal of Neurosurgery* 83:621-626, 1995.
153. Seppälä MT, Sainio MA, Haltia MJ, Kinnunen JJ, Setälä KH, Jääskeläinen JE. Multiple schwannomas: schwannomatosis or neurofibromatosis type 2? *Journal of Neurosurgery* 89:36-41, 1998.
154. Sidky YA, Borden EC. Inhibition of angiogenesis by interferons: effects on tumor- and lymphocyte-induced vascular responses. *Cancer Research* 47:5155-5161, 1987.
155. Sigelman J. Retinal diseases. Pathogenesis, laser therapy and surgery. Little, Brown and Company. Boston, 1984.
156. Standard SC, Ahuja A, Livingston K, Guterman LR, Hopkins LN. Endovascular embolization and surgical excision for the treatment of cerebellar and brain stem hemangioblastomas. *Surg Neurol* 41:405-410, 1994.
157. Steinbach F, Novick AC, Zincke H, Miller DP, Williams RD, Lund G, Skinner DG, Esrig D, Richie JP, deKernion JB, et al. Treatment of renal cell carcinoma in von Hippel-Lindau disease: a multicenter study. *J Urol* 153:1812-1816, 1995.

158. Steiner L, Leksell L, Greitz T, Forster DM, Backlund EO. Stereotaxic radiosurgery for cerebral arteriovenous malformations. Report of a case. *Acta Chir Scand* 138:459-464, 1972.
159. Steiner L, Lindquist C, Adler JR, Torner JC, Alves W, Steiner M. Clinical outcome of radiosurgery for cerebral arteriovenous malformations. *J Neurosurg* 77:1-8, 1992.
160. Steiner L, Lindquist C, Steiner M. Radiosurgery. *Adv Tech Stand Neurosurg* 19:19-102, 1992.
161. Stolle C, Glenn G, Zbar B, Humphrey JS, Choyke P, Walther M, Pack S, Hurley K, Andrey C, Klausner R, Linehan WM. Improved detection of germline mutations in the von Hippel-Lindau disease tumor suppressor gene. *Hum Mutat* 12:417-423, 1998.
162. Stratmann R, Krieg M, Haas R, Plate KH. Putative control of angiogenesis in hemangioblastomas by the von Hippel-Lindau tumor suppressor gene. *J Neuropathol Exp Neurol* 56:1242-1252, 1997.
163. Symon L, Murota T, Pell M, Bordi L. Surgical management of haemangioblastoma of the posterior fossa. *Acta Neurochir* 120:103-110, 1993.
164. Tampieri D, Leblanc R, TerBrugge K. Preoperative embolization of brain and spinal hemangioblastomas. *Neurosurgery* 33:502-505 discussion 505, 1993.
165. Taylor PC, Dolan G, Ng JP, Paul B, Collin R, Reilly JT. Efficacy of recombinant interferon-alpha (rIFN-alpha) in polycythaemia vera: a study of 17 patients and an analysis of published data. *Br J Haematol* 92:55-59, 1996.
166. Teppo L, Pukkala E, Lehtonen M. Data quality and quality control of a population-based cancer registry. Experience in Finland. *Acta Oncol* 33:365-369, 1994.
167. Tibbs RE, Harkey HL, Raila FA. Hemangioblastoma of the filum terminale: case report. *Neurosurgery* 44:221-223, 1999.
168. Tsugaya M, Kajita A, Hayashi Y, Okamura T, Kohri K, Kato Y. Detection and monitoring of simple renal cysts with computed tomography. *Urol Int* 54:128-131, 1995.
169. Webster AR, Maher ER, Bird AC, Gregor ZJ, Moore AT. A clinical and molecular genetic analysis of solitary ocular angioma. *Ophthalmology* 106:623-629, 1999.
170. Webster AR, Maher ER, Moore AT. Clinical characteristics of ocular angiomatosis in von Hippel-Lindau disease and correlation with germline mutation. *Arch Ophthalmol* 117:371-378, 1999.

171. Webster AR, Richards FM, MacRonal FE, Moore AT, Maher ER. An analysis of phenotypic variation in the familial cancer syndrome von Hippel-Lindau disease: evidence for modifier effects. *Am J Hum Genet* 63:1025-1035, 1998.
172. Whitson JT, Welch RB, Green WR. von Hippel-Lindau disease: case report of a patient with spontaneous regression of a retinal angioma. *Retina* 6:253-259, 1986.
173. Vial T, Descotes J. Contact sensitization assays in guinea-pigs: are they predictive of the potential for systemic allergic reactions? *Toxicology* 93:63-75, 1994.
174. Wittebol-Post D, Hes FJ, Lips CJM. The eye in von Hippel-Lindau disease. Long-term follow-up of screening and treatment: recommendations. *J Intern Med* 243:555-561, 1998.
175. Witten FR, O'Brien DPd, Sewell CW, Wheatley JK. Bilateral clear cell papillary cystadenoma of the epididymides presenting as infertility: an early manifestation of von Hippel-Lindau's syndrome. *J Urol* 133:1062-1064, 1985.
176. von Hippel E. Die anatomische Grundlage der von mir beschriebenen "sehr seltenen Erkrankung der Netzhaut". *Arch Ophthalmol* 79:350-377, 1911.
177. Yimoyines DJ, Topilow HW, Abedin S, McMeel JW. Bilateral peripapillary exophytic retinal hemangioblastomas. *Ophthalmology* 89:1388-1392, 1982.
178. Zbar B, Kishida T, Chen F, Schmidt L, Maher ER, Richards FM, Crossey PA, Webster AR, Affara NA, Ferguson-Smith MA, Brauch H, Glavac D, Neumann HP, Tisherman S, Mulvihill JJ, Gross DJ, Shuin T, Whaley J, Seizinger B, Kley N, Olschwang S, Boisson C, Richard S, Lips CH, Lerman M, et al. Germline mutations in the von Hippel-Lindau disease (VHL) gene in families from North America, Europe, and Japan. *Hum Mutat* 8:348-357, 1996.